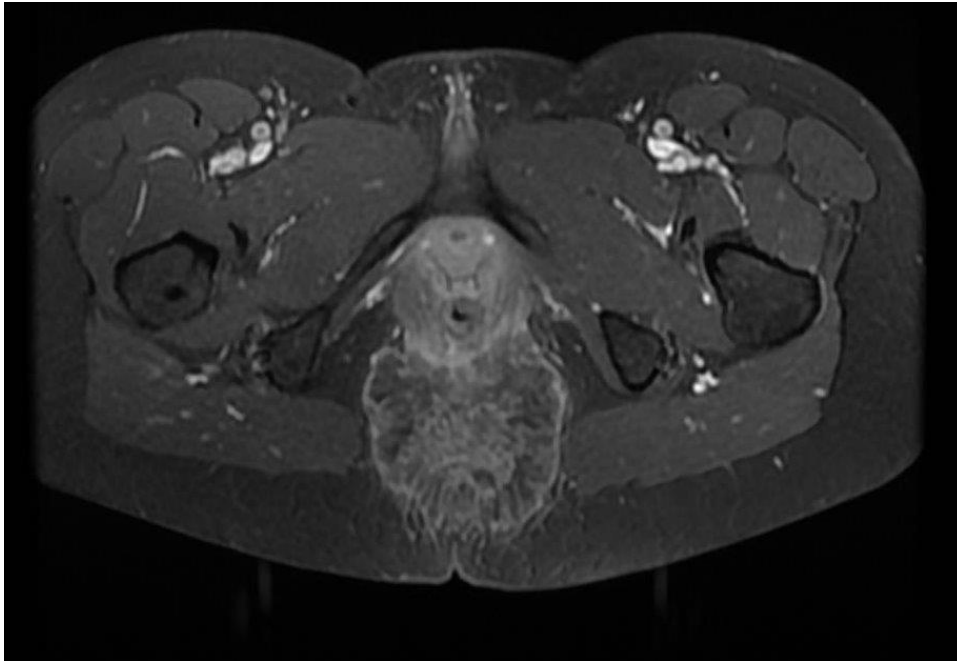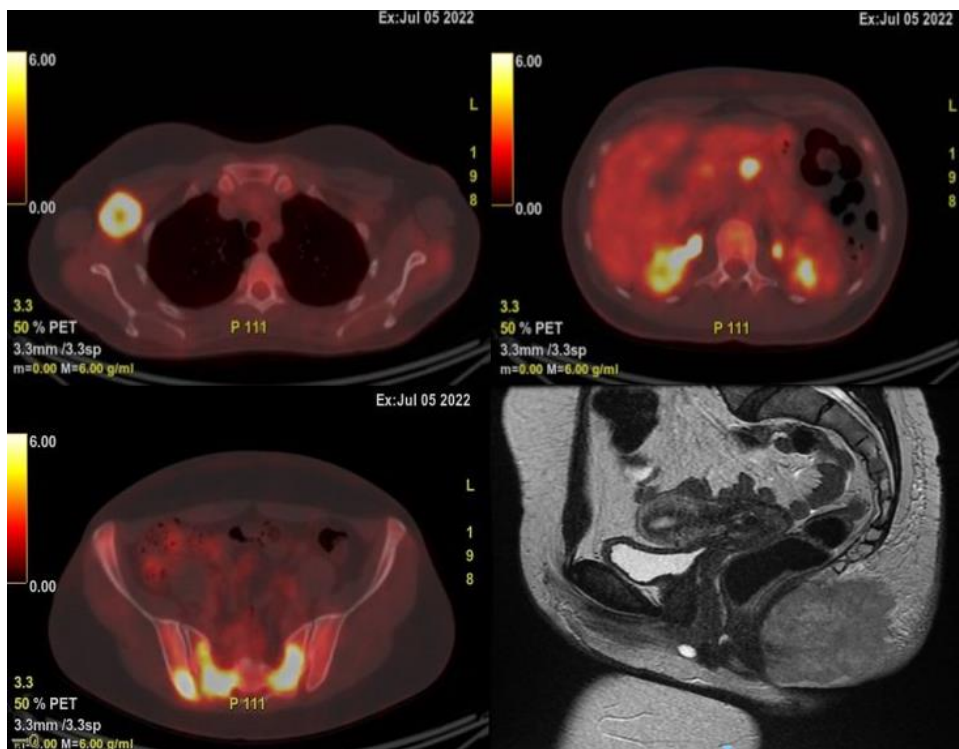


RM Axial T1 fat-sat post Gd, showing marked enhancement post contrast.



Axial fusion PET-CT showing metastasis. RM sagittal T2 showing the localization of perineal mass.