

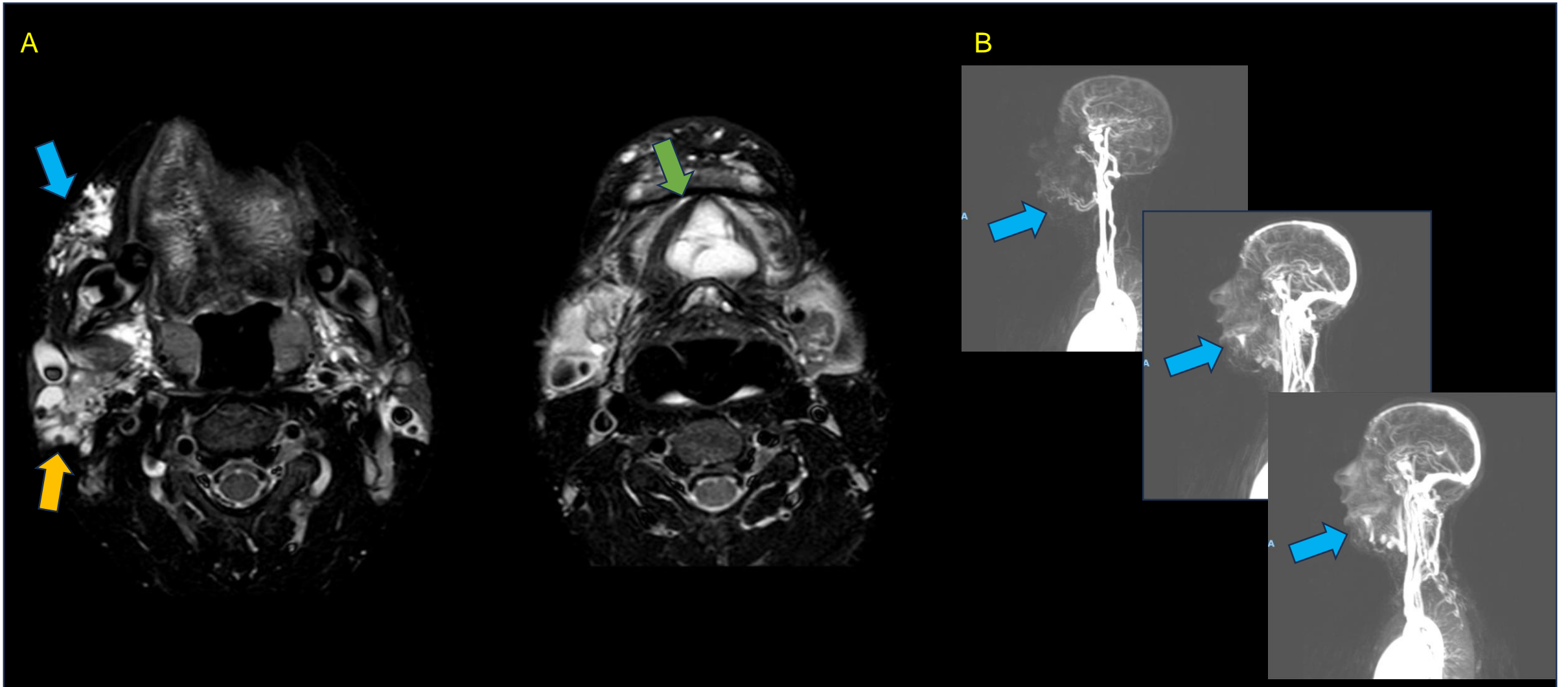Figure 1: Multi-site Veno-lymphatic Malformation on Face. **A:** MRI, axial STIR. Micro and macrocystic lesions scattered throughout the skin, subcutaneous tissue of the face, and superficial anterior and lateral cervical spaces. **Blue arrow:** dilation and ectasia of the right external jugular vein. **Yellow arrow:** thrombophlebitis. **Green arrow:** venous pouches with slow and progressive opacification in the submental region. **B:** MRI, Dynamic angiographic study. **Blue arrow:** Lesion in the floor of the oral cavity, with heterogeneous enhancement after intravenous injection of contrast media. The angiographic study reveals filling of arterial and venous patterns (predominantly venous) with ectasia of retromandibular veins, which may be associated with arteriovenous microfistula.

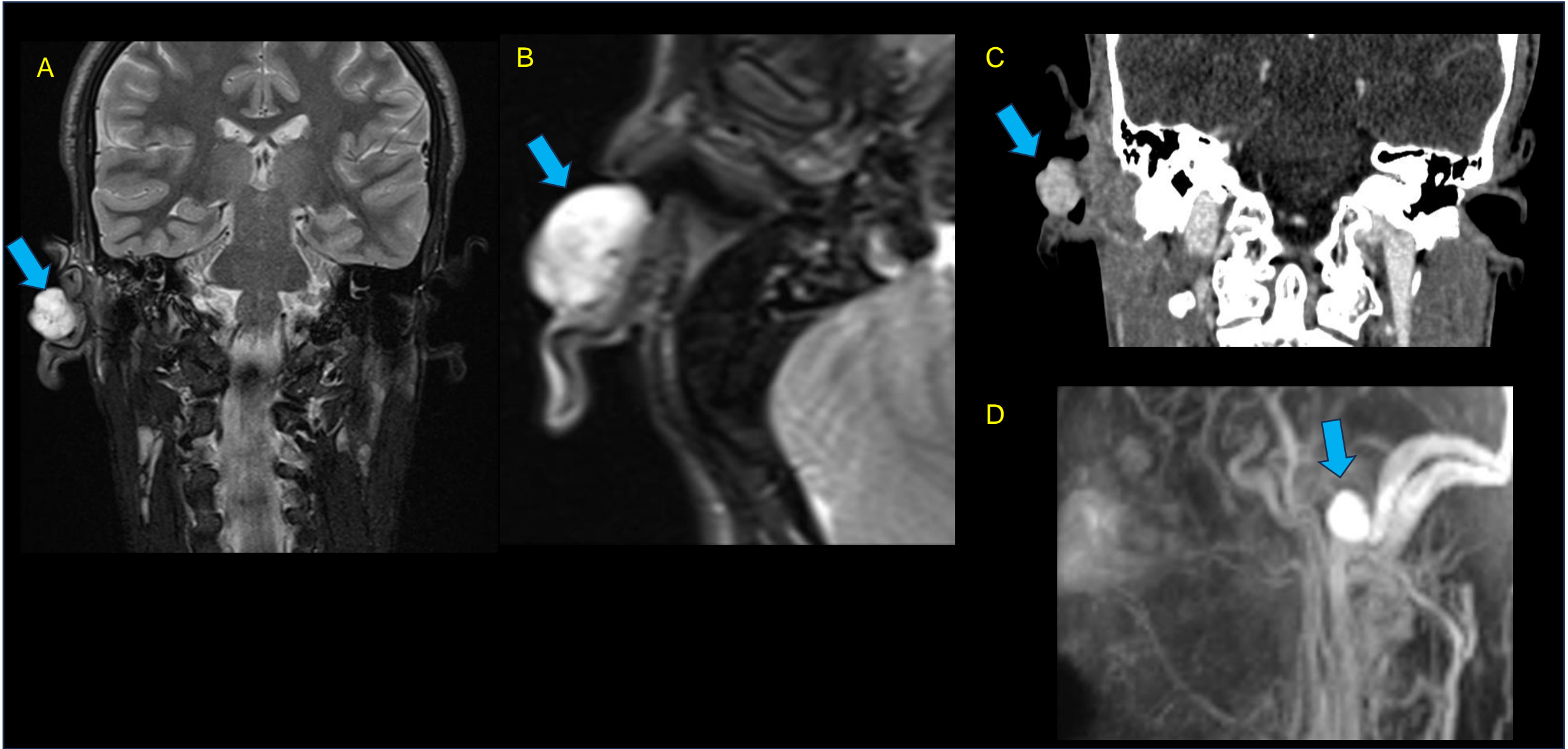


Figure 2: Lobular Capillary Hemangioma in the right external ear. **Blue arrow:** lesion located on cavum conchae. **A:** MRI, coronal STIR. **B:** MRI, axial STIR. **C:** Contrast-Enhanced Computed Tomography, coronal. **D:** MRI, dynamic angiographic study shows vascular component with arterial pattern filling, with branches from the posterior auricular artery, and the presence of large drainage veins.

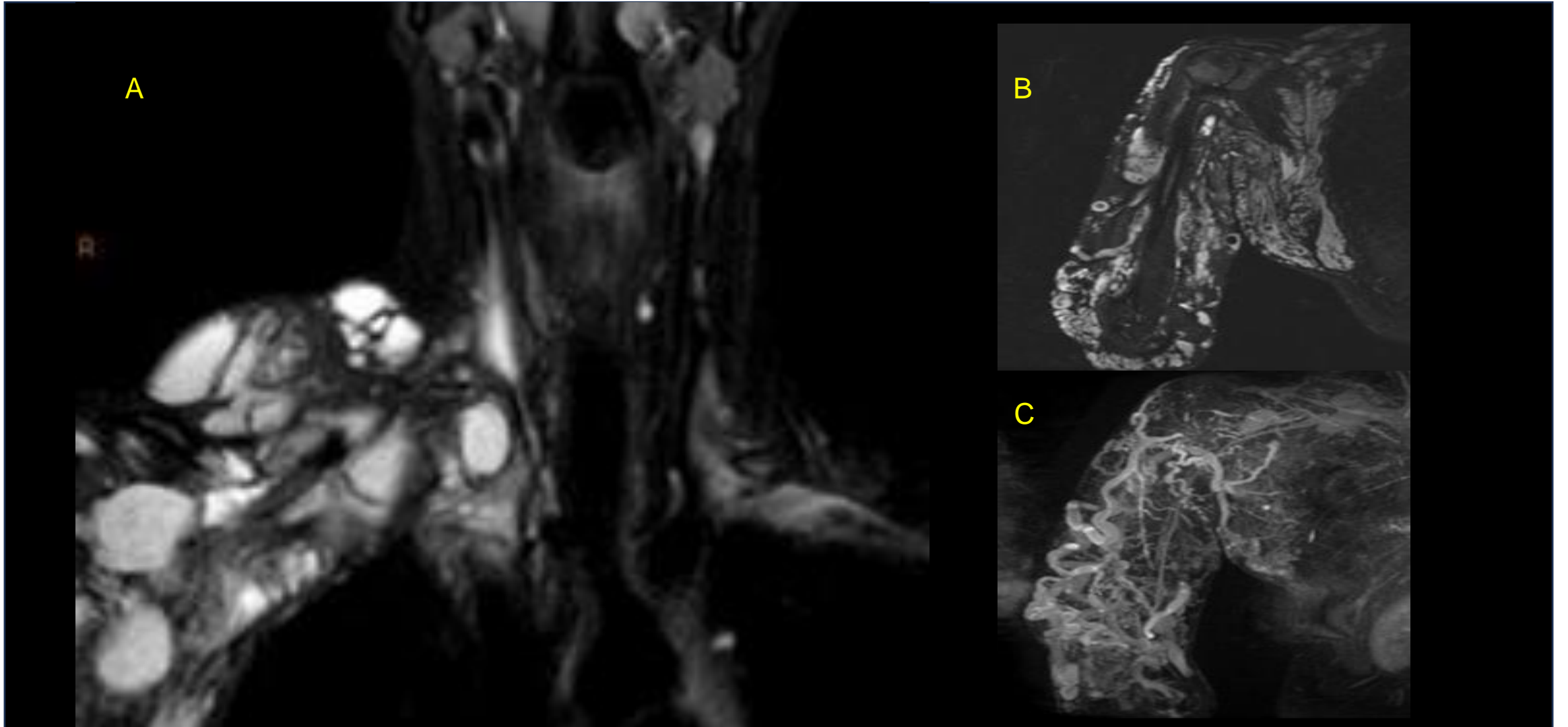


Figure 3: Upper Limb Arteriovenous Fistula. **A:** MRI, coronal STIR. **B:** MRI, coronal, arterial phase dynamic angiographic sequence. **C:** MRI, MIP reformation from arterial phase dynamic angiographic sequence. MRI shows abnormal direct communication between adjacent artery and vein characterized by early opacification of adjacent veins in the region of the arteriovenous fistula. Additionally, veins are dilated in response to high-flow arterialization.

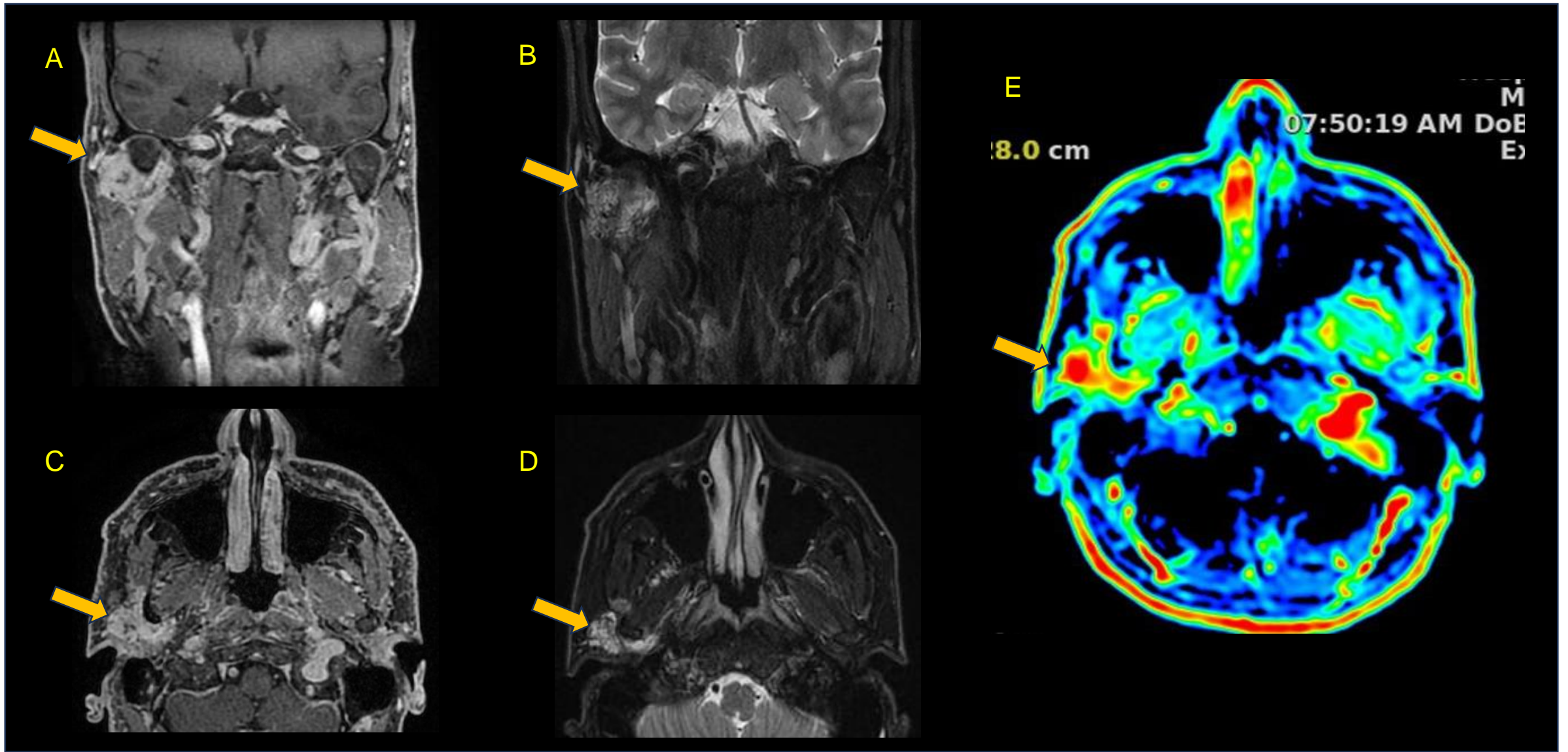


Figure 4: Parotid Venous Malformation. **A:** MRI, coronal T1. **B:** MRI, coronal T2 STIR. **C:** MRI, axial T1. **D:** MRI, axial T2 STIR. **E:** Permeability map. **Yellow arrow:** MRI shows lobulated nodular lesion in the upper third of the right parotid gland, involving the mandibular condylar process, without bone erosions, characterized by isosignal on T1, heterogeneous hypersignal on T2, and post-contrast enhancement, with increased perfusion on the color map.

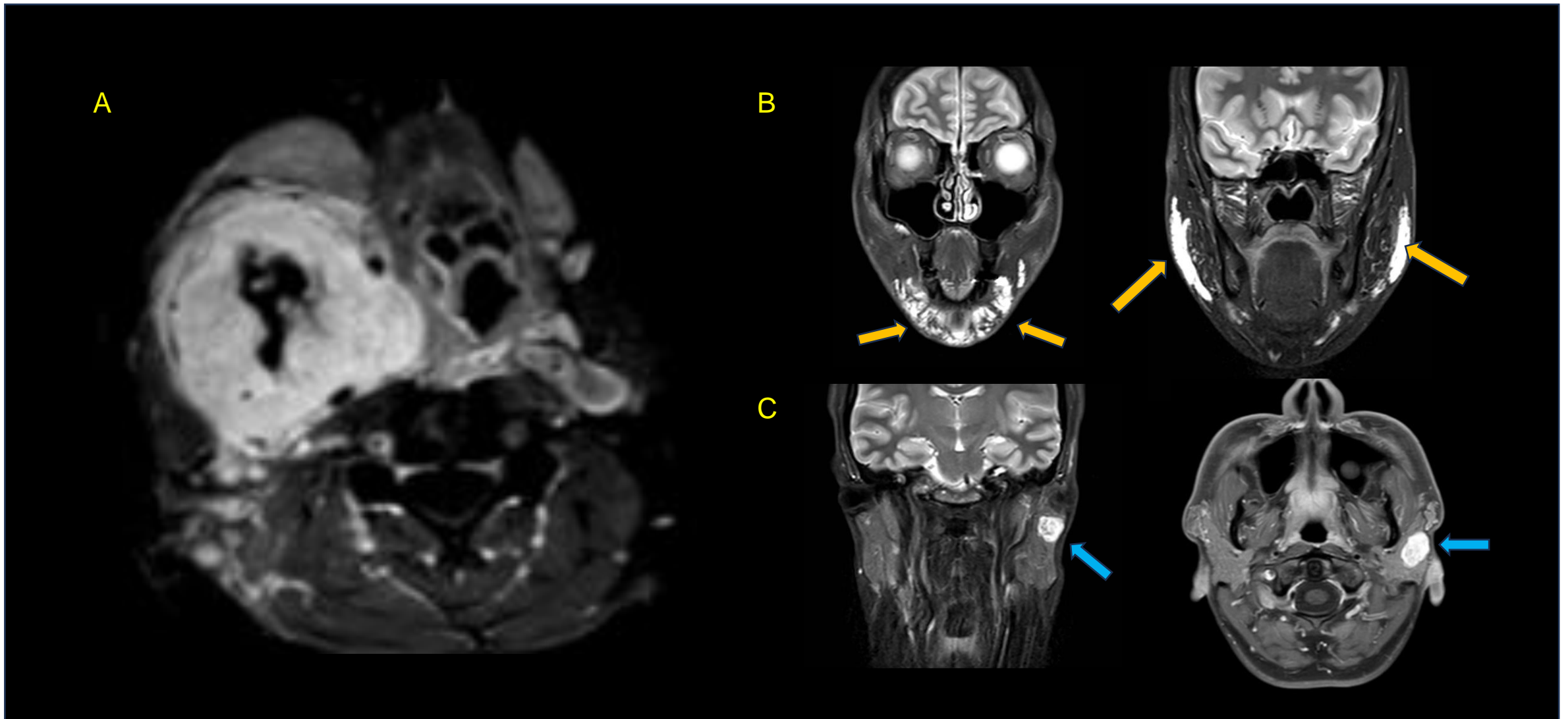


Figure 5: Some differential diagnoses for vascular anomalies. **A:** Paraganglioma. **B:** Changes secondary to aesthetic procedure (facial harmonization). **C:** Pleomorphic adenoma.