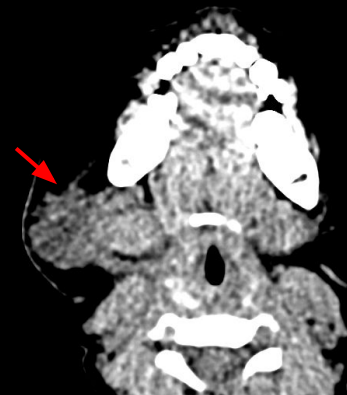
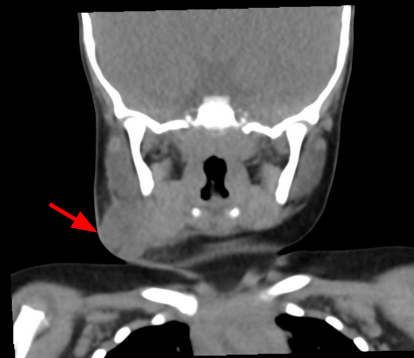
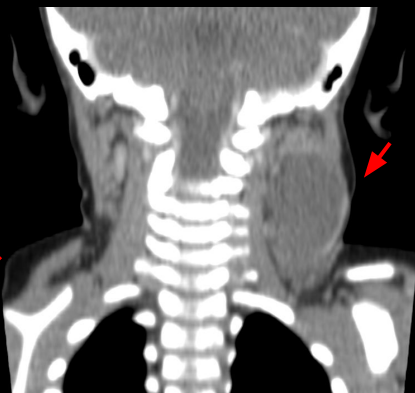
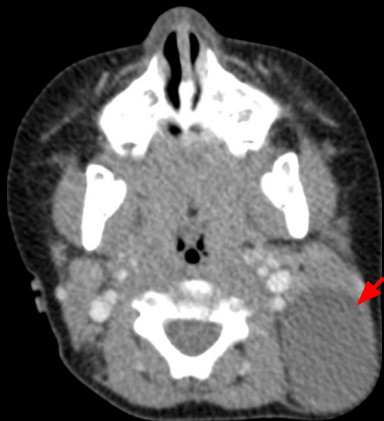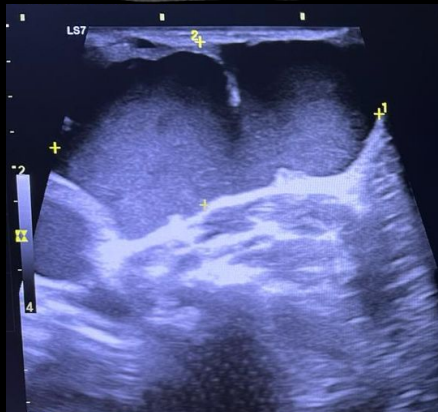


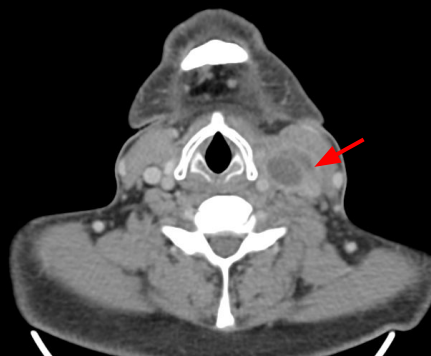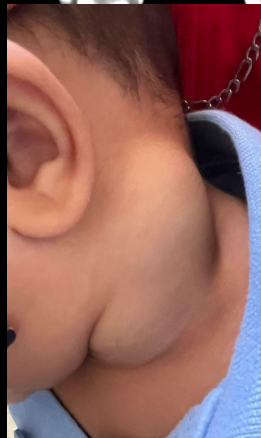CABEÇA E PESCOÇO NO PRONTO SOCORRO, ALÉM DAS FRATURAS: UM GUIA PARA RESIDENTES



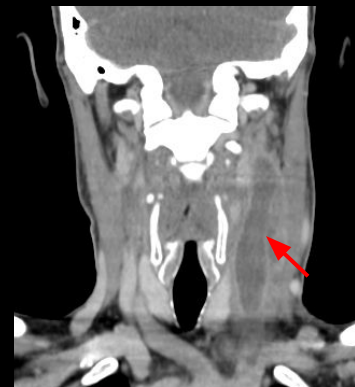Cisto da fenda branquial infectado

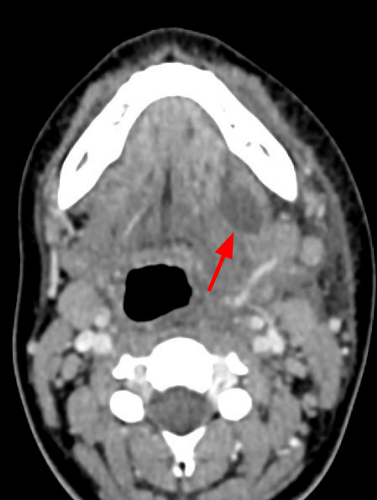
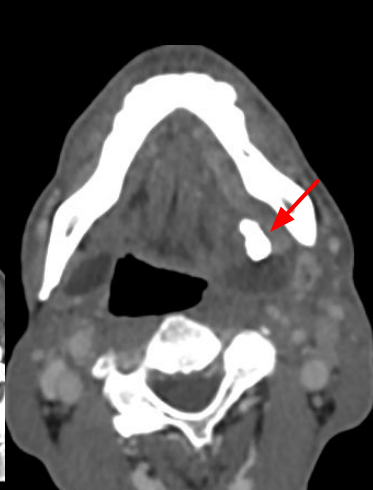
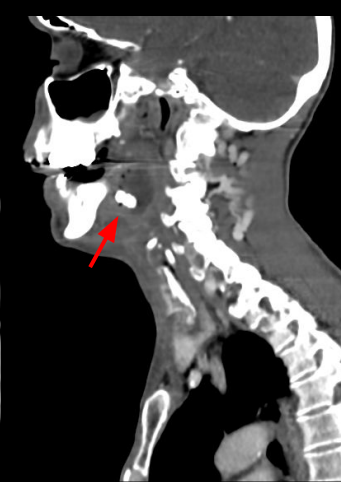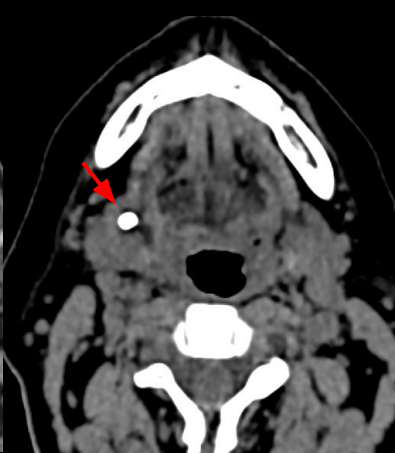
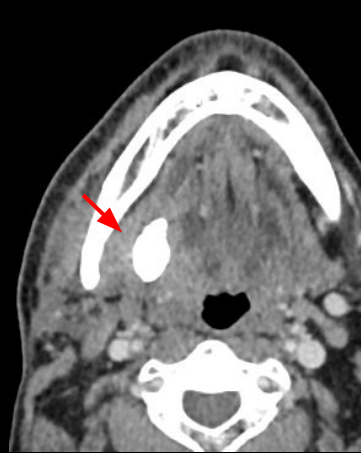


Linfangioma



Abscesso de Bezold - trombose da veia jugular

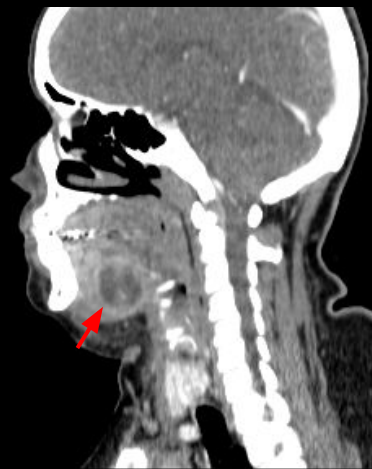
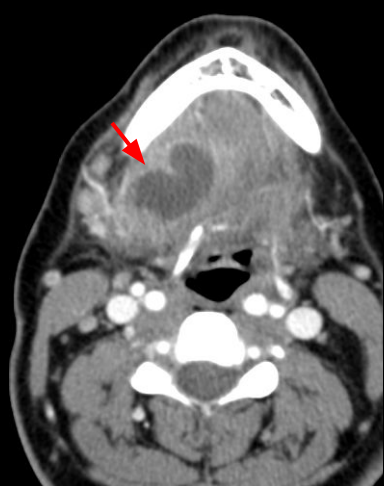


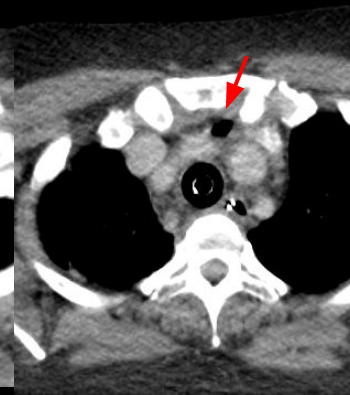
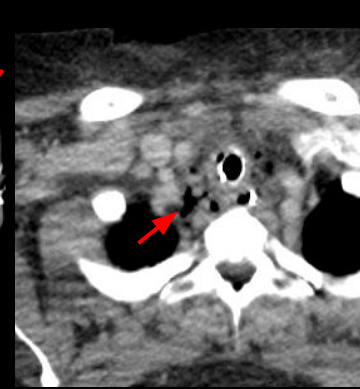
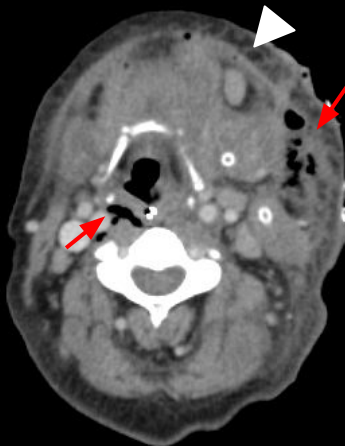
Sialolítase

Sialolítase

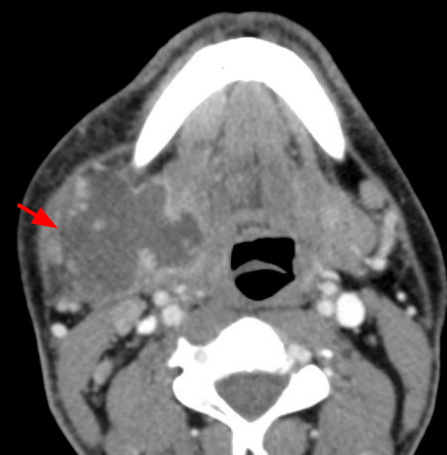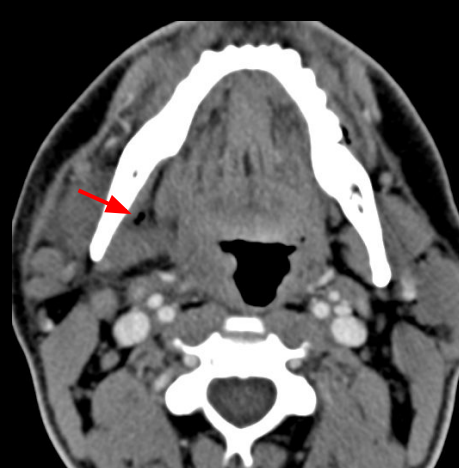
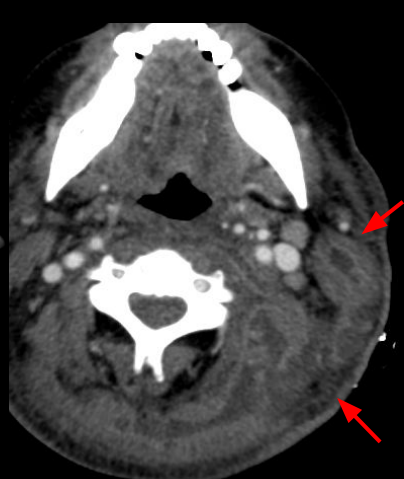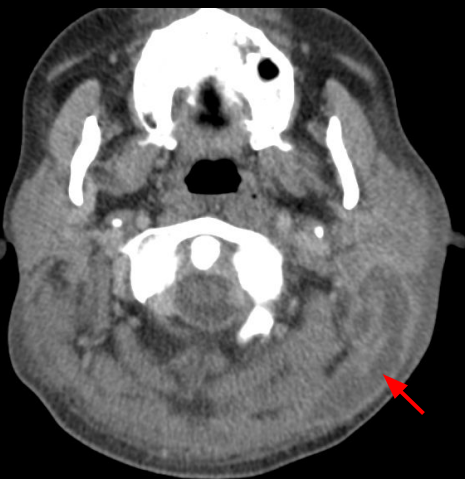Coleção



Coleção

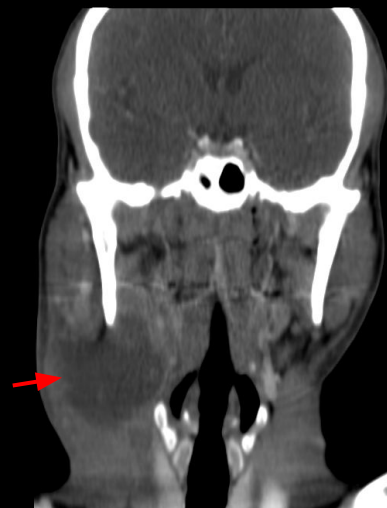
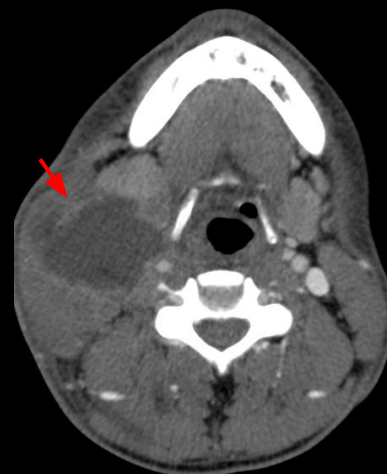
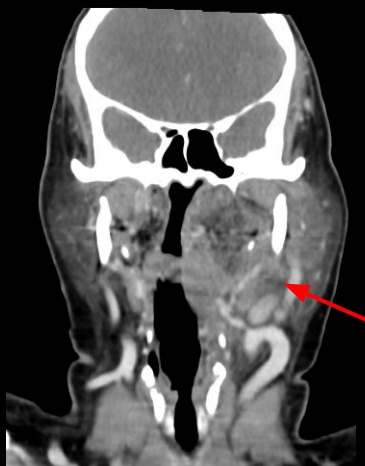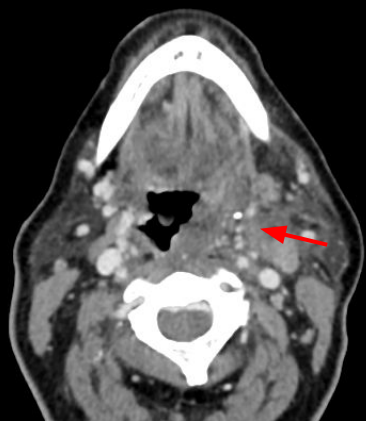


Abscesso cervical com mediastinite



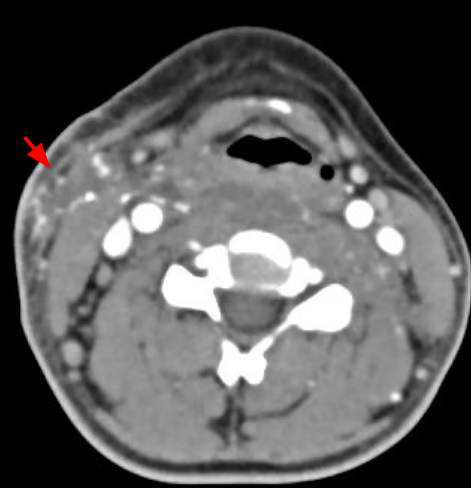
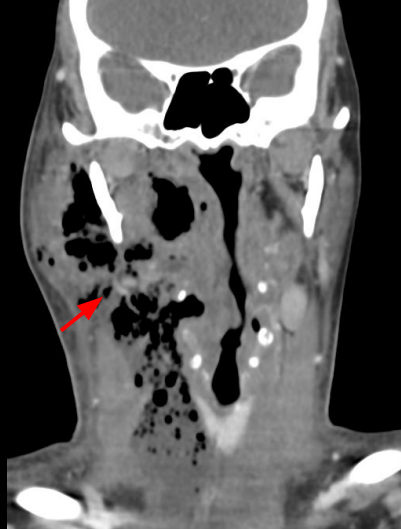
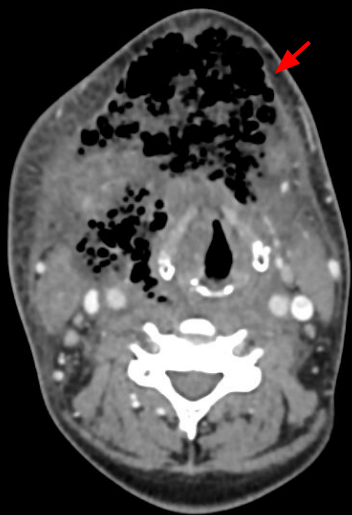
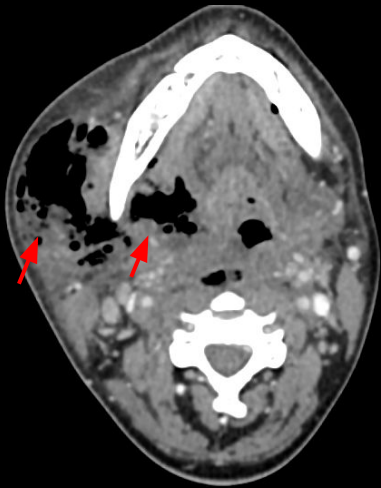
Coleção após passagem de acesso venoso

Coleção → evolução após 7 dias



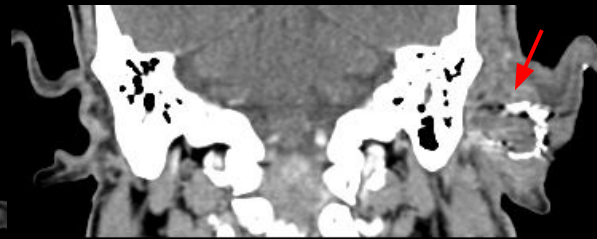
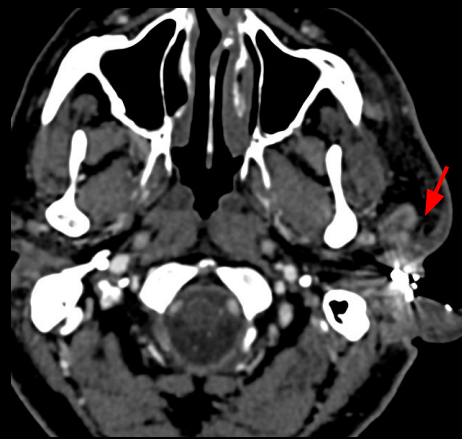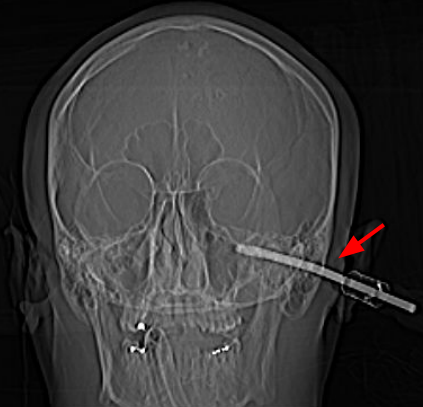
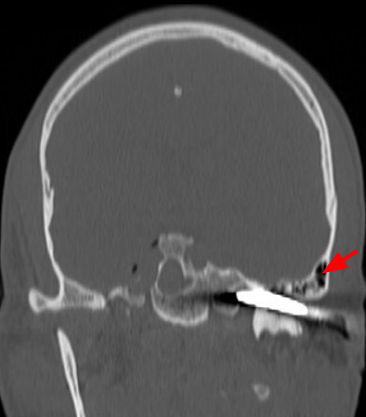
Sialolftiase complicada com abscesso

Coleção



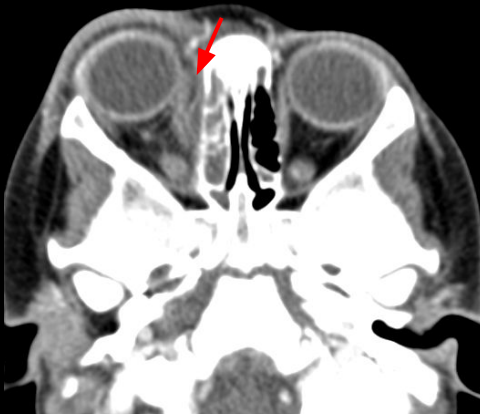
Abscesso cervical

Lesão por arma de fogo com rastilhos

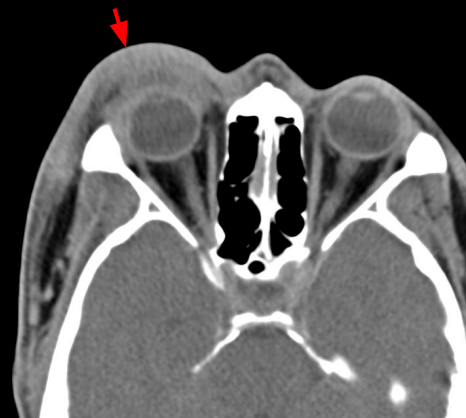
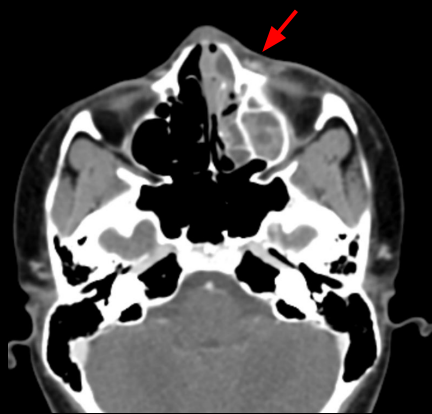


Corpo estranho

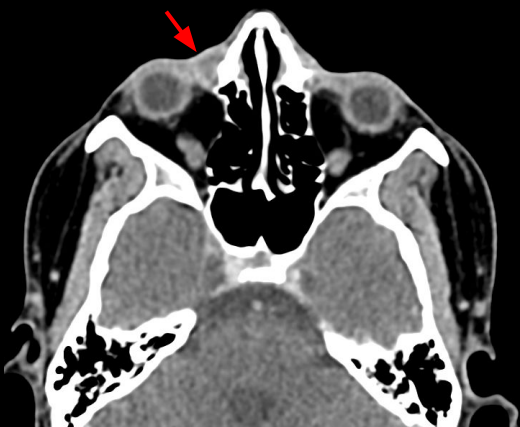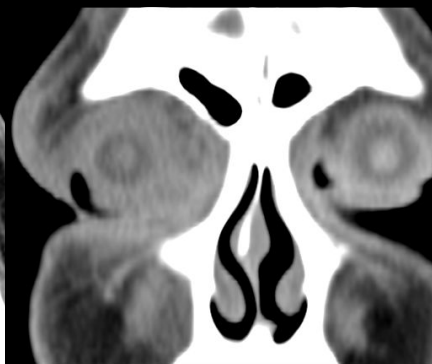
Mífase



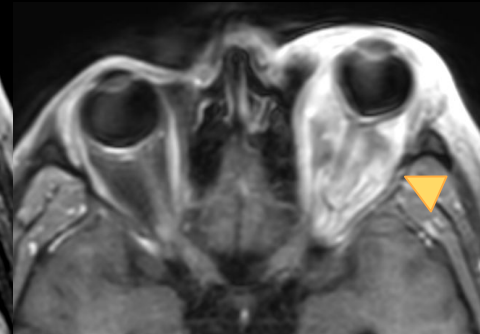
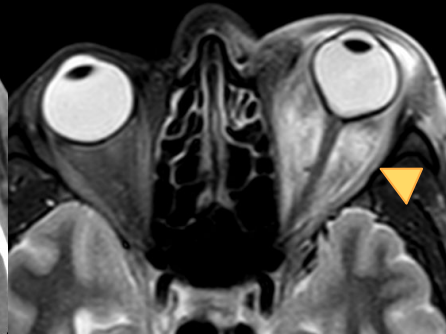
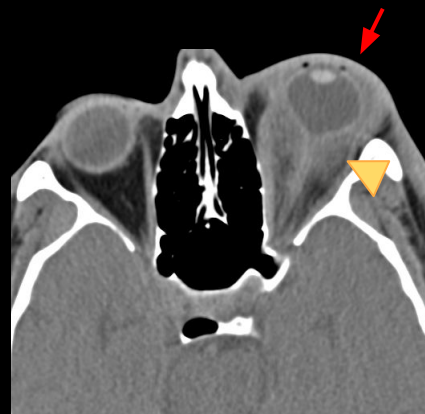
Abscesso subperiosteal



Celulite periorbitária pré septal



Dacriocistite



Celulite periorbitária pós septal