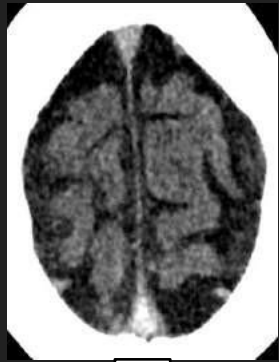

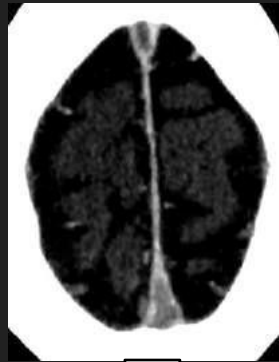# Trombose Venosa Cerebral: desvendando sua evolução e complicações

Achados de Imagem Típicos de Trombose Venosa Cerebral na TC

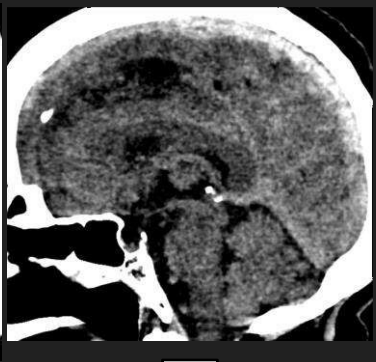
AGUDA E SUBAGUDA (<15D)



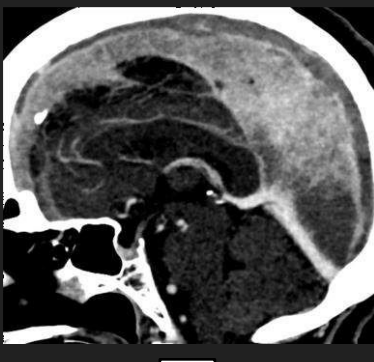
NCCT



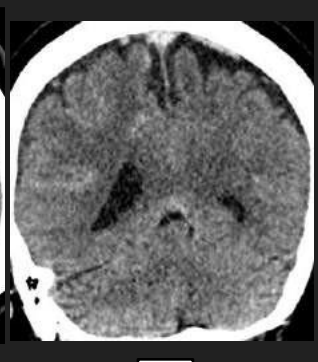
CECT



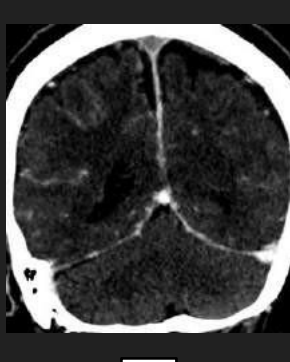
NCCT



CECT

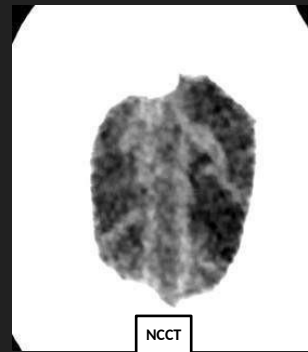
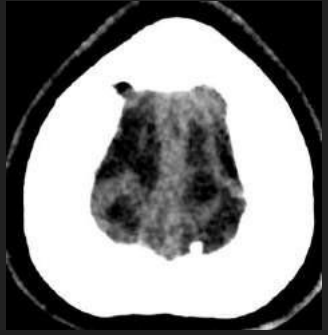


NCCT

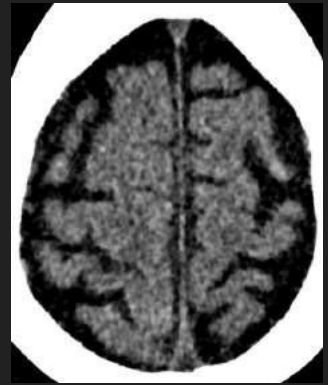


CECT

CRÔNICA (>15D)

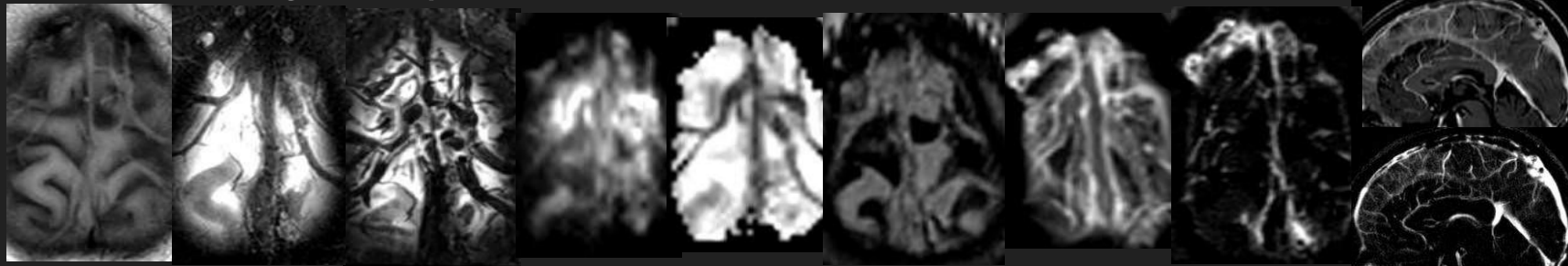


NCCT

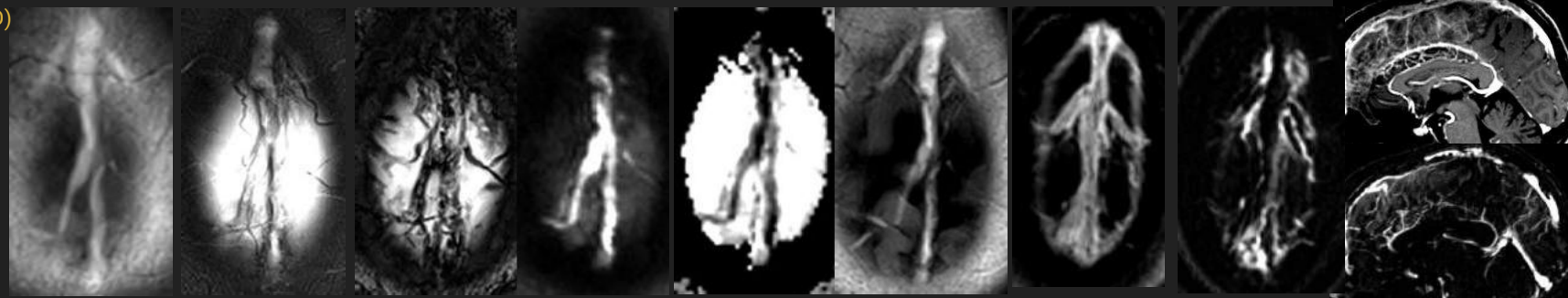


# Achados de Imagem Típicos de Trombose Venosa Cerebral na RM

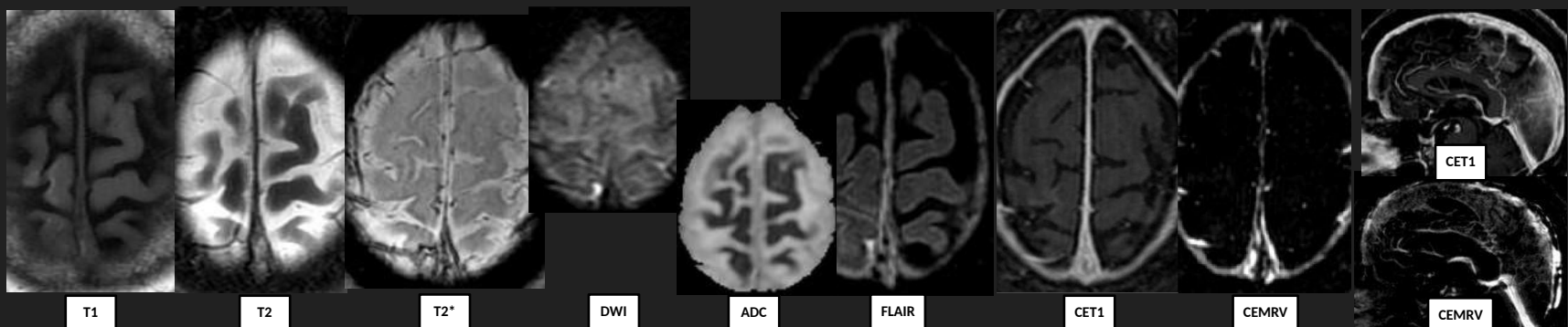
AGUDA (0-5D)  
DEOXYHb



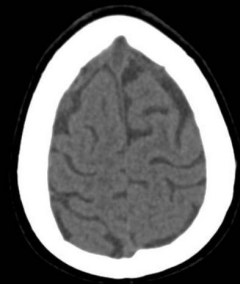
SUBAGUDA (6-15D)  
METHb



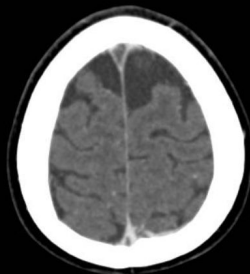CRÔNICA (>15D)



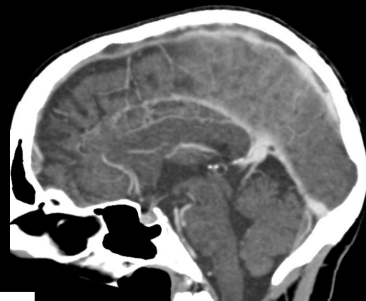# Evolução da Trombose Venosa Cerebral



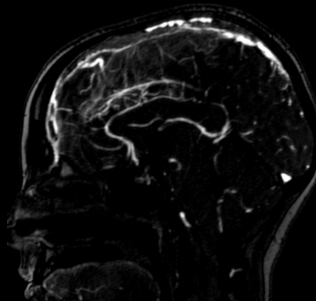
NCCT



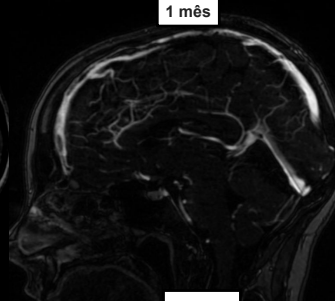
CECT



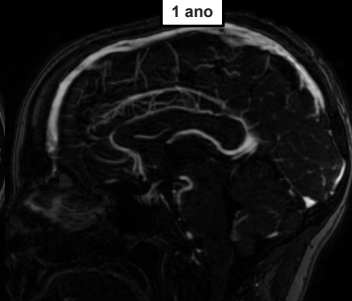
CECT



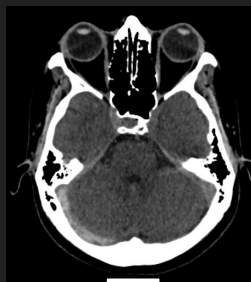1 mês



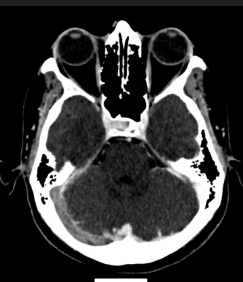CEMRV



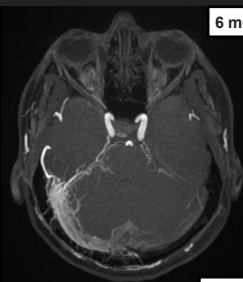1 ano



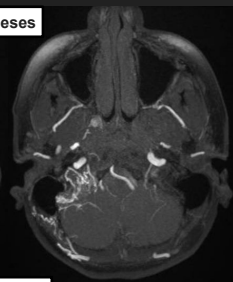
NCCT



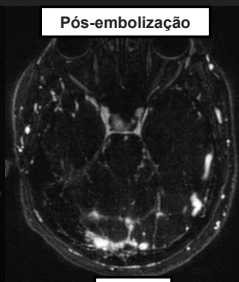
CECT



ANGIOTOF



6 meses

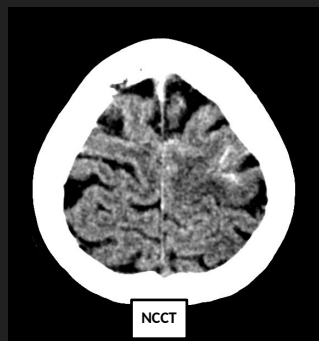


CEMRV

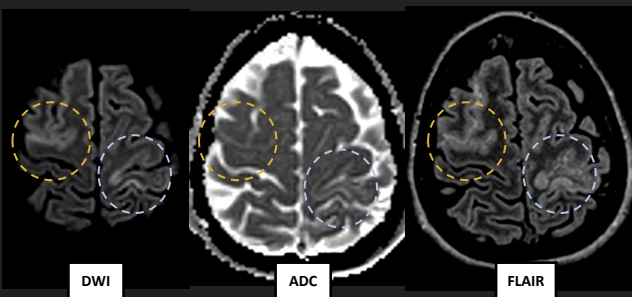
Pós-embolização

# Complicações da Trombose Venosa Cerebral

Edema/Infarto venoso na TC

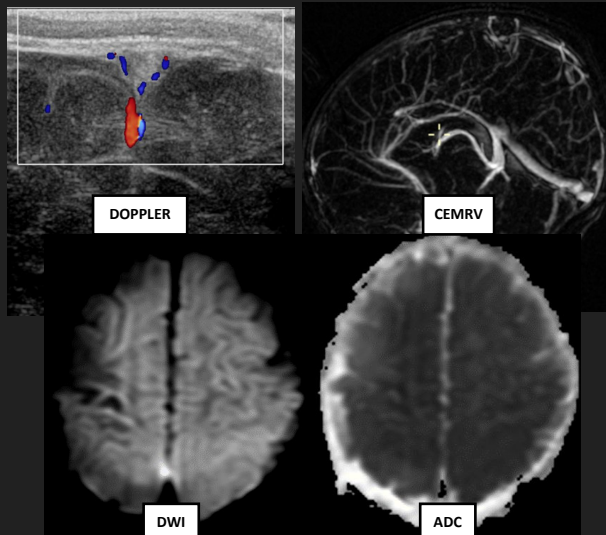


Edema + Infarto venoso na RM

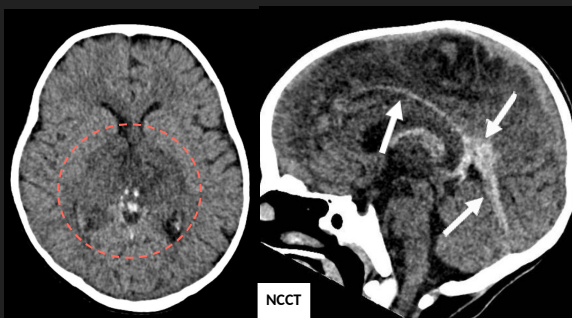
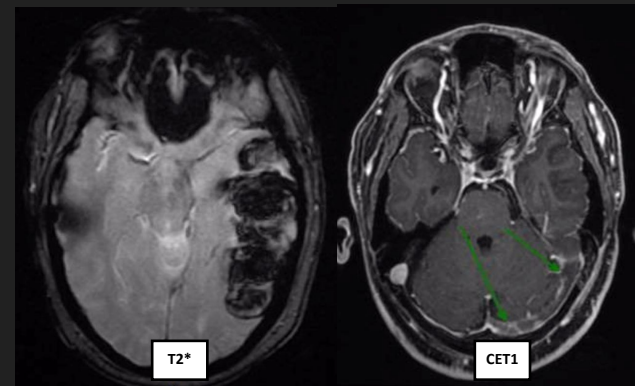
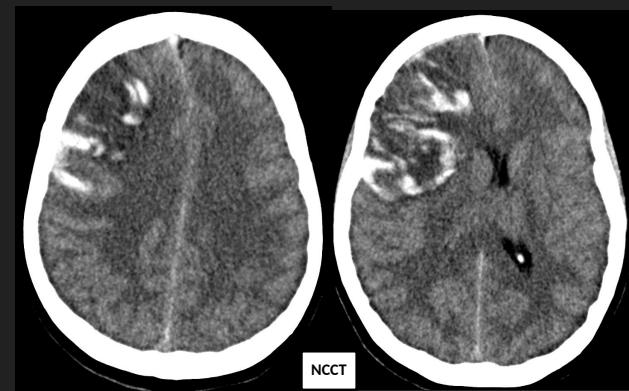


+ HSA padrão convexidade

Infarto venoso



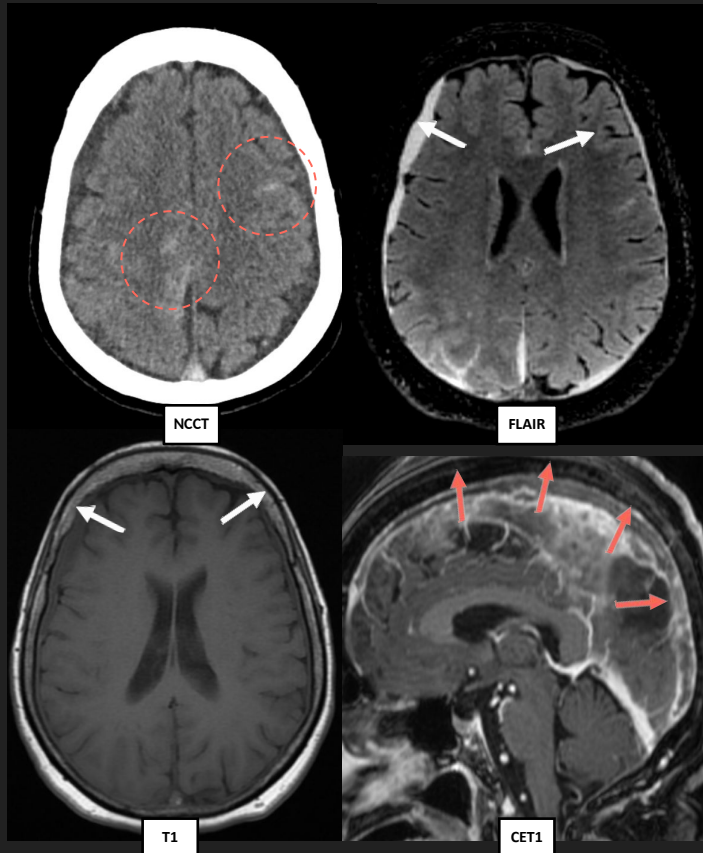
Infarto hemorrágico





# Complicações da Trombose Venosa Cerebral

Hemorragia subaracnóide (padrão convexidade) +  
Hematomas subdurais



Fístula arteriovenosa

