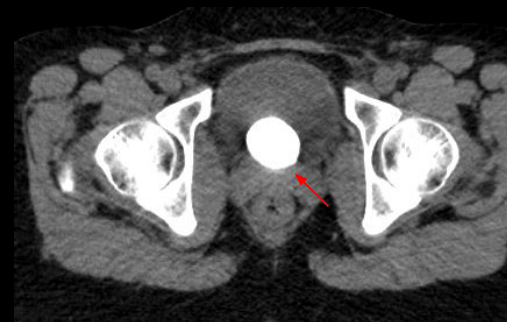
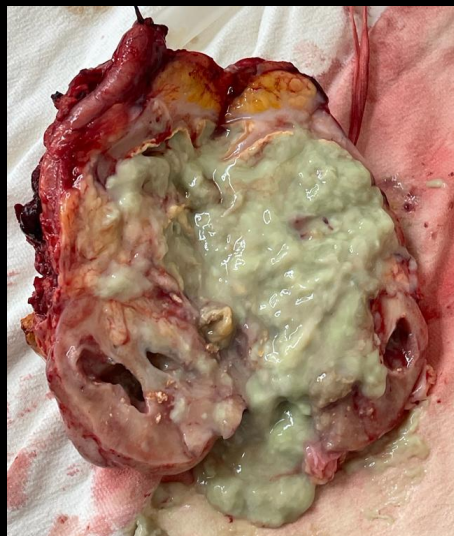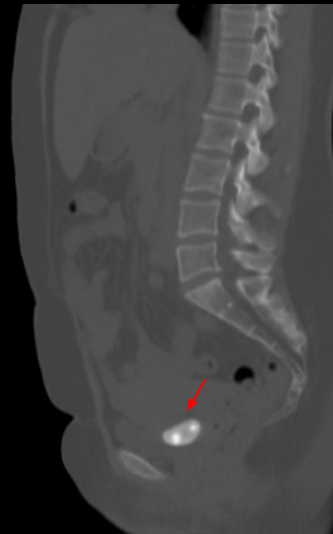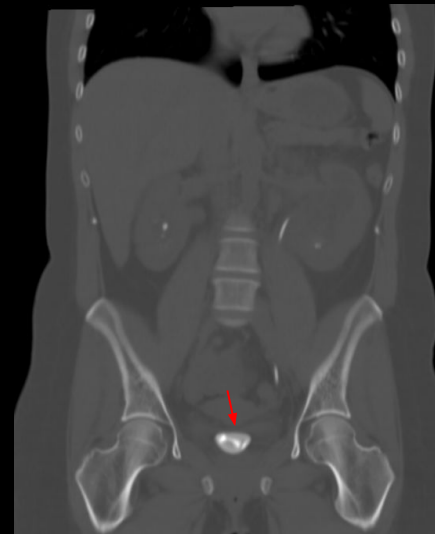
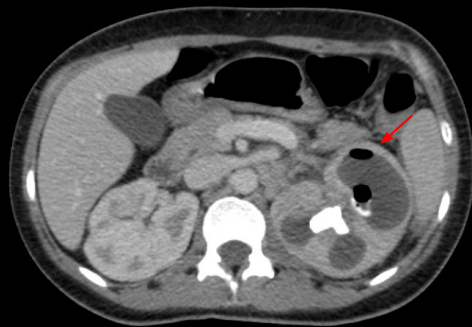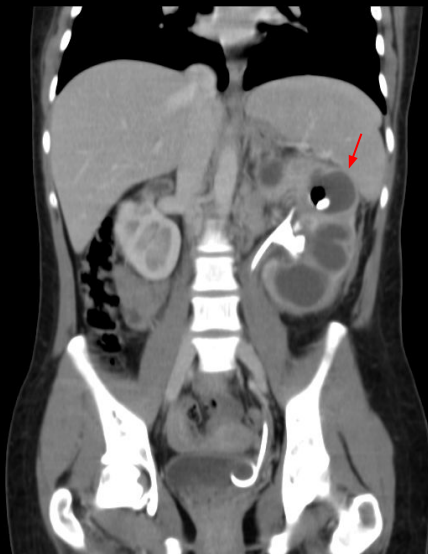
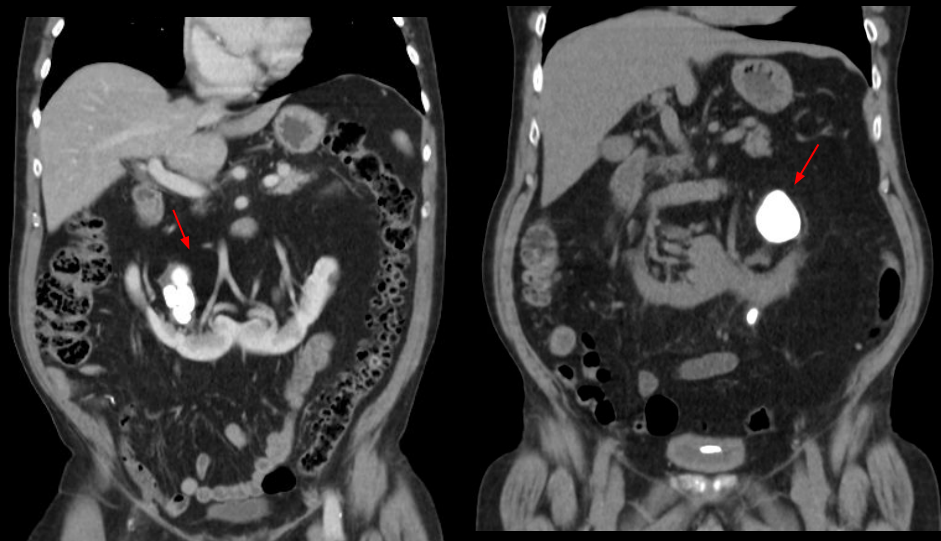


UROLITÍASE NA TOMOGRAFIA: DO SIMPLES AO COMPLICADO, O QUE O RADIOLOGISTA PRECISA SABER.

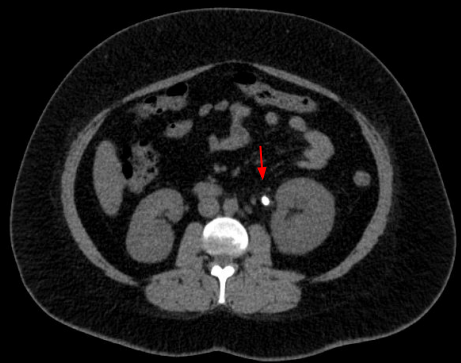
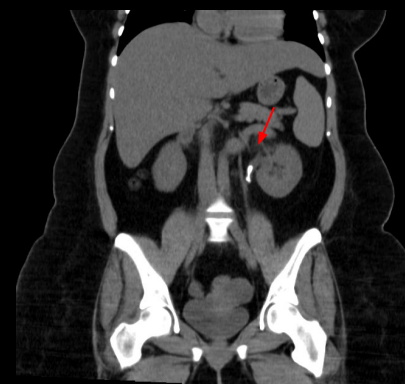
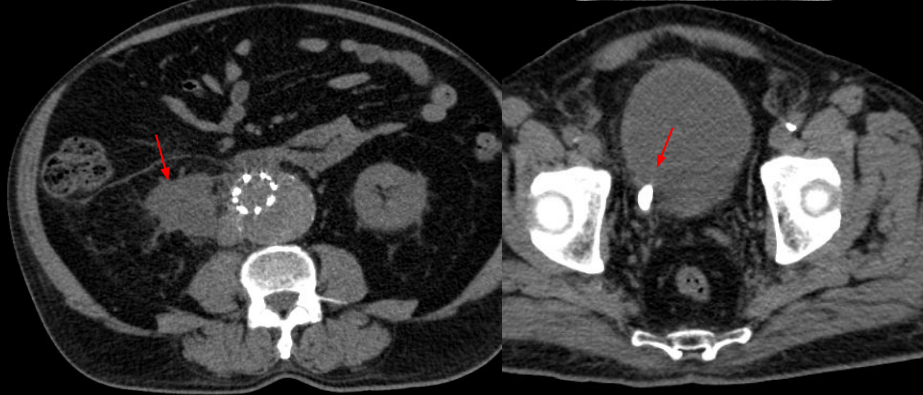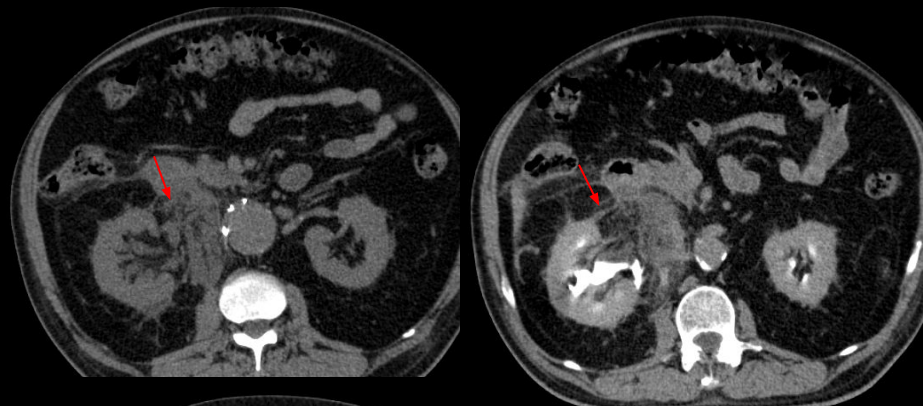


Pielonefrite
xantogranulomatosa

Calcificação
de catéter
duplo J

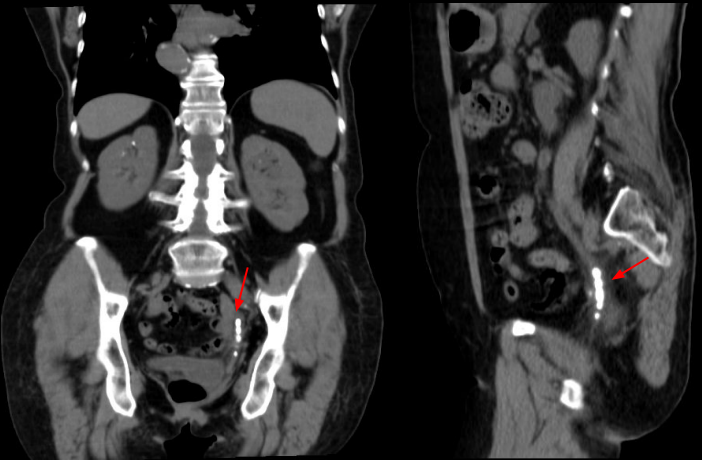


Rins em ferradura com cálculos coraliformes

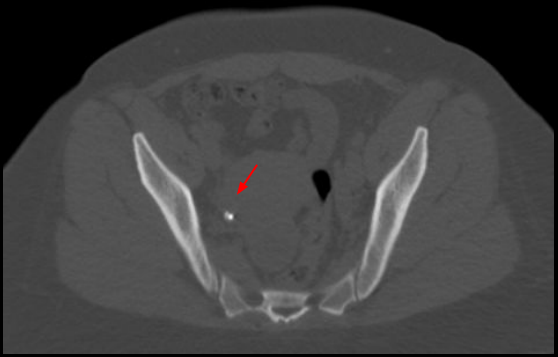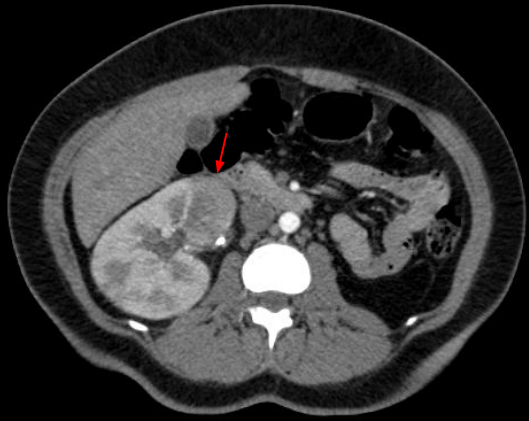


Cálculo na junção ureteropielica

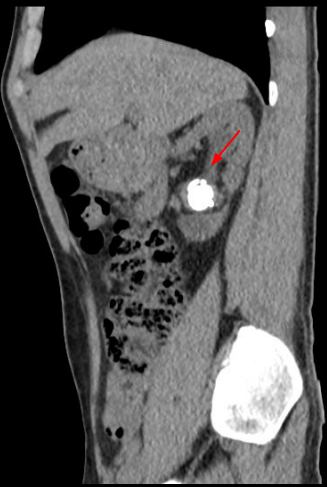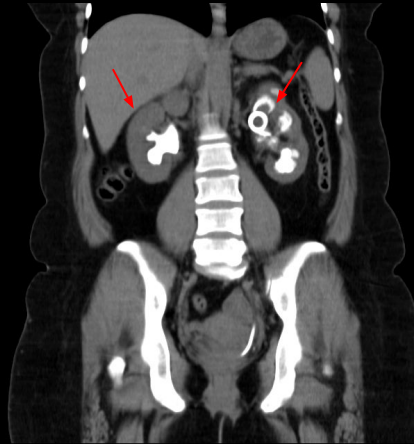
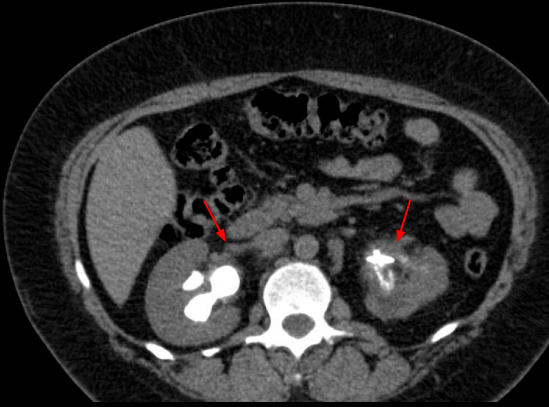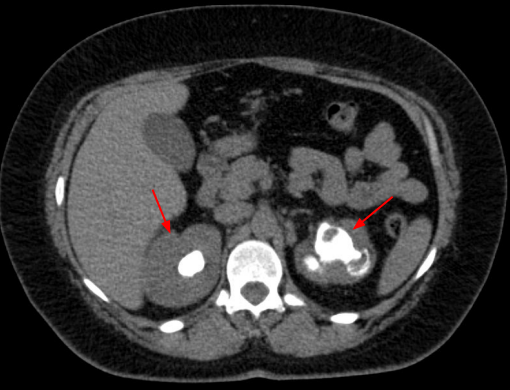
Rotura de ureter após passagem de cálculo



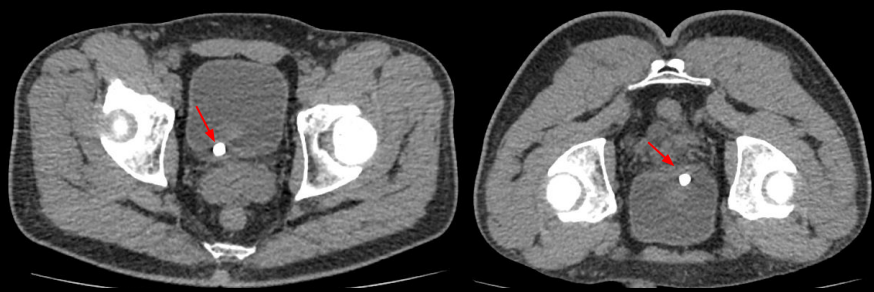
Múltiplos cálculos no ureter distal



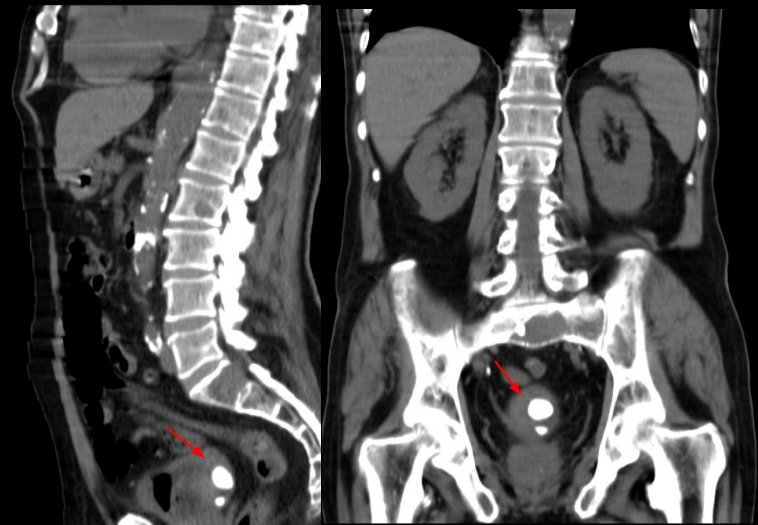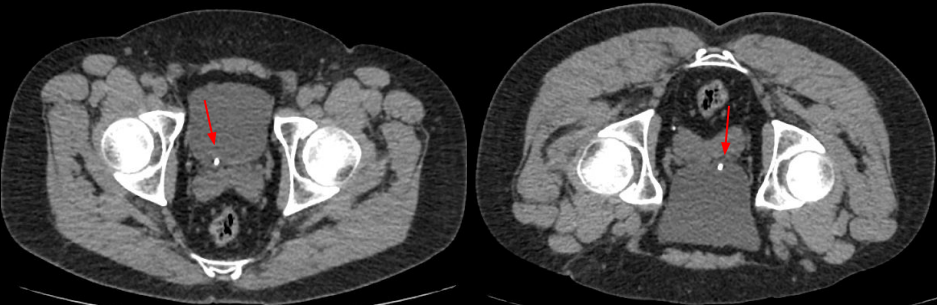
Pielonefrite obstrutiva



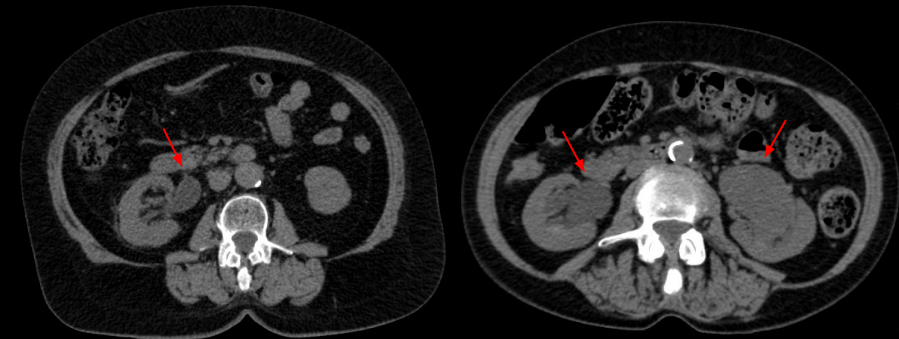Cálculos coraliformes



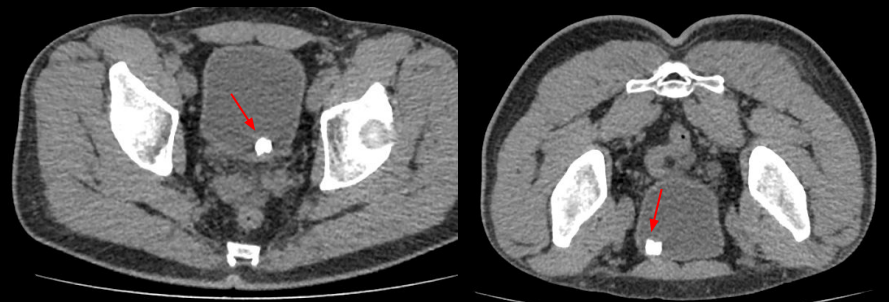
Cálculos na junção ureterovesical



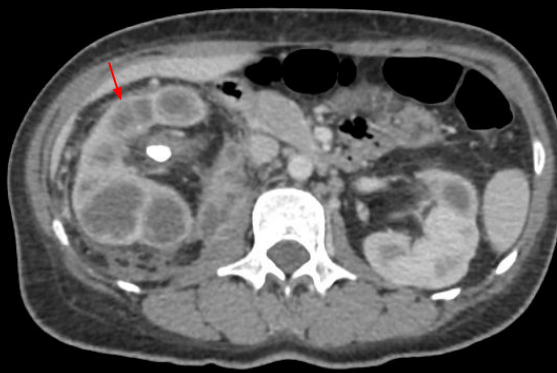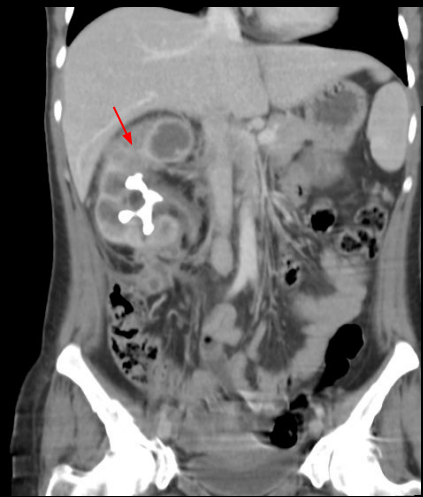Cálculos vesicais



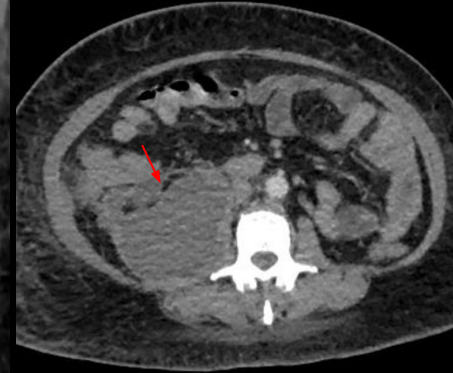
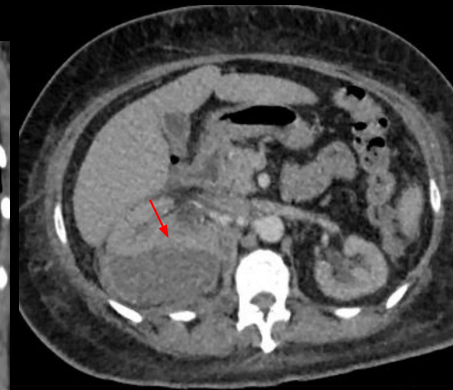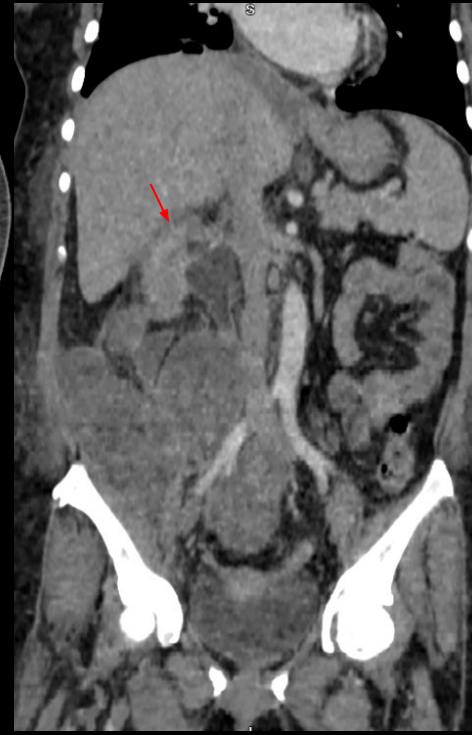Hidronefrose



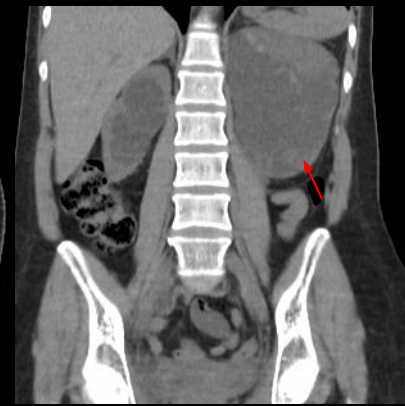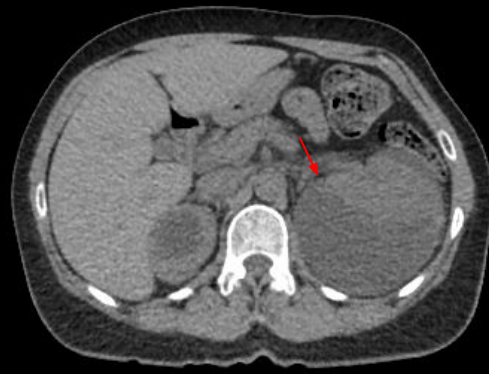
Cálculo vesical móvel a mudança de decúbito



Pielonefrite obstrutiva



Coleção subcapsular com extensão para o ílio psoas e retroperitônio, secundária à pielonefrite



Coleção subcapsular