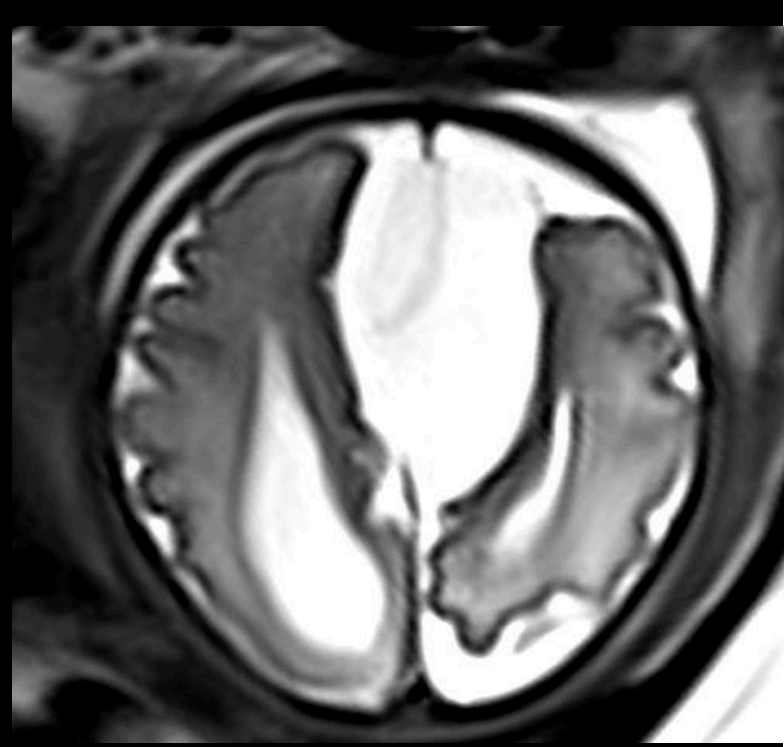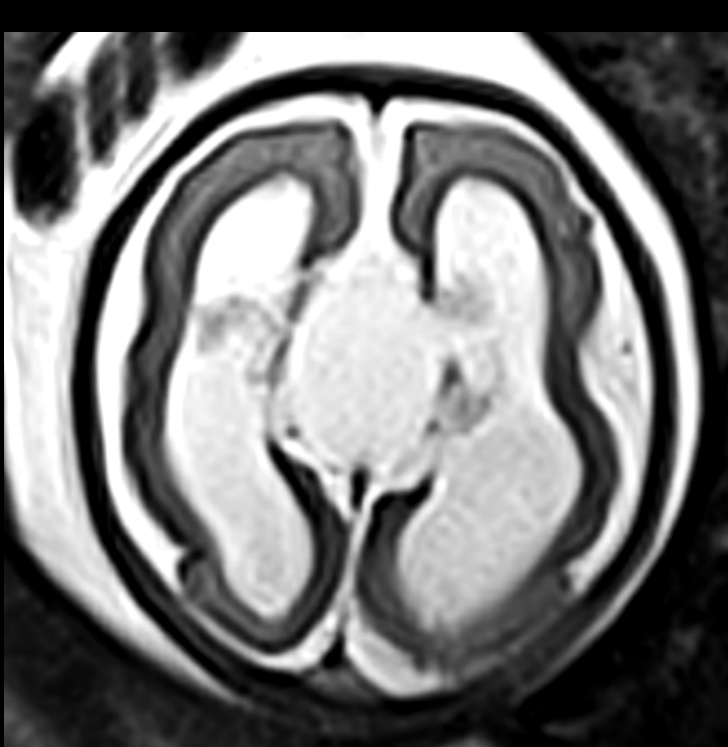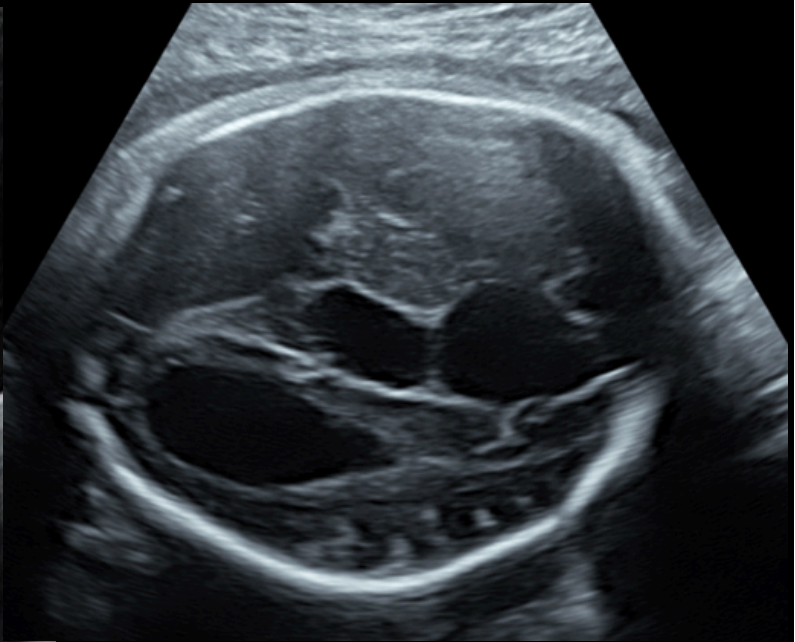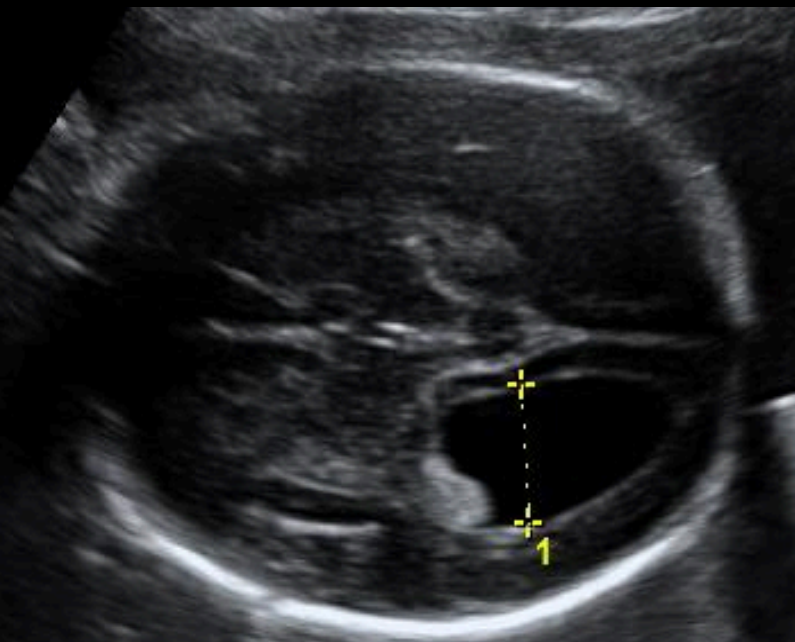
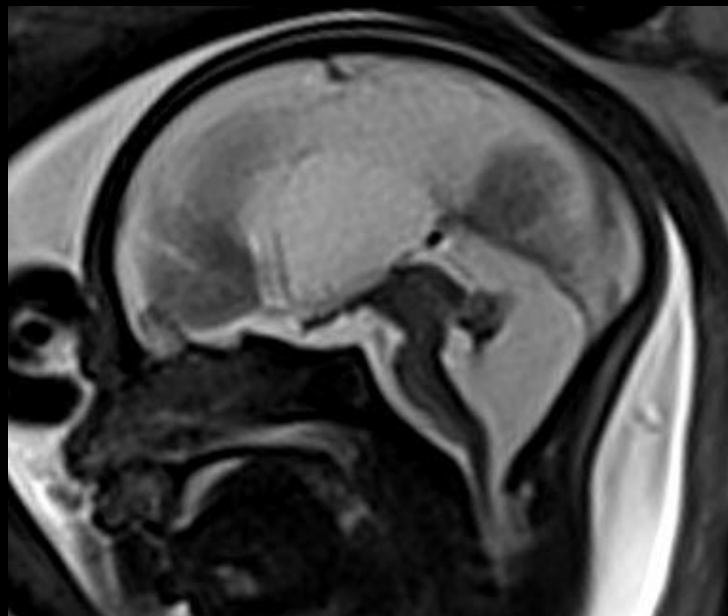


Fetal MRI Axial T2 showing the asymmetric ventriculomegaly and an interhemispheric cyst.



Obstetric US showing the asymmetric ventriculomegaly and an interhemispheric cyst.



MRI sagittal T2 showing the dysgenesis of the corpus callosum