

Figura 01: Radiografía de tórax.

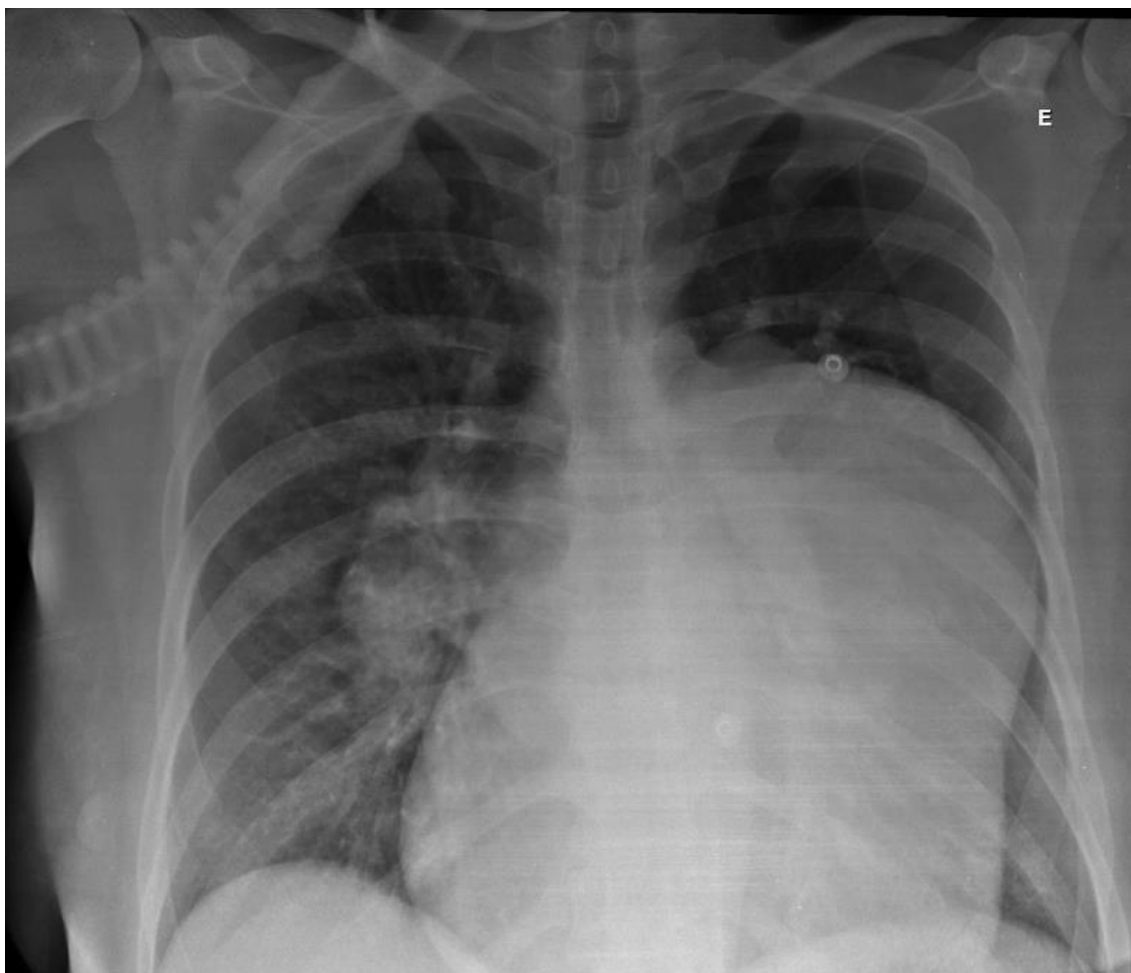


Figura 02: Corte axial de tomografia computadorizada de tórax com contraste.

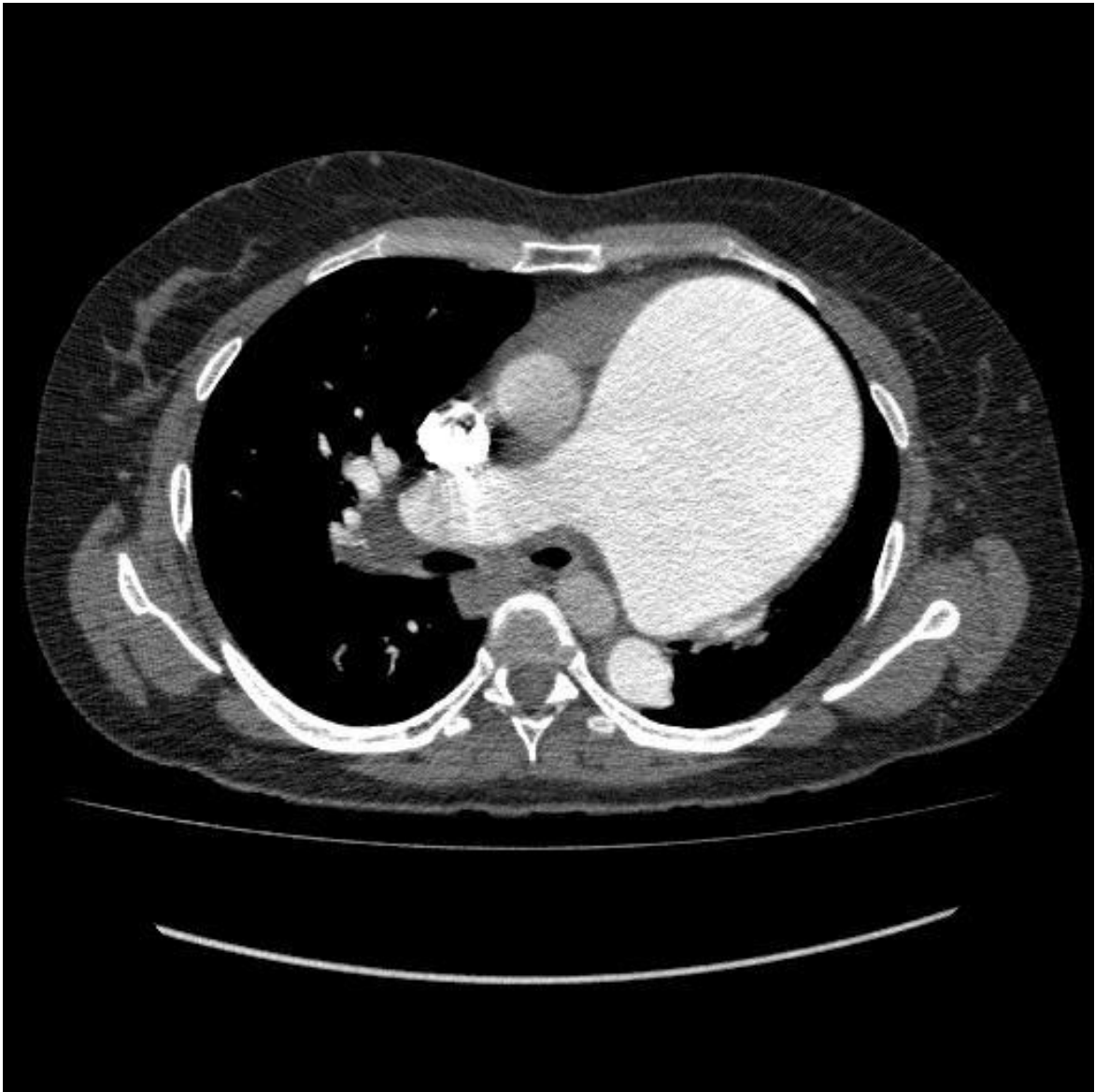


Figura 03: Reconstrução tridimensional do tronco da artéria pulmonar.

