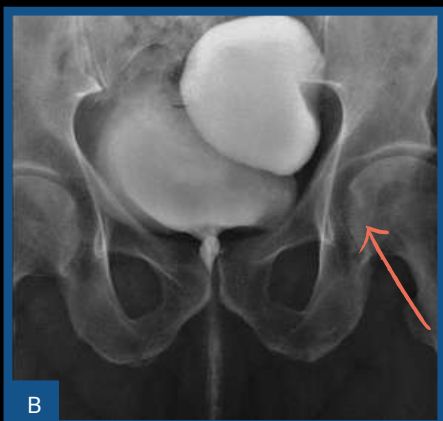
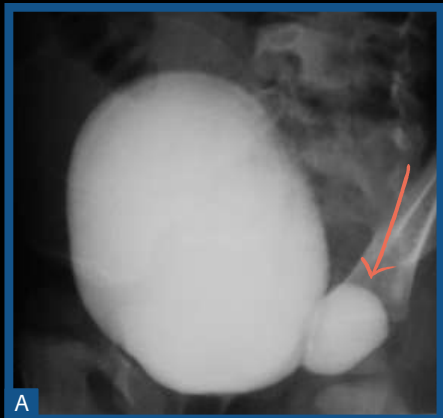
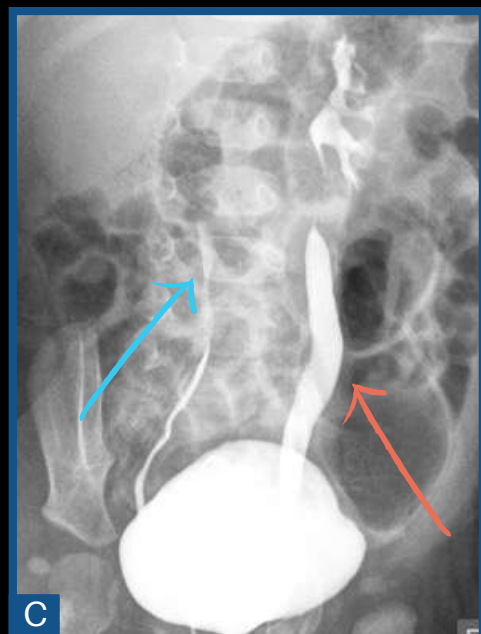
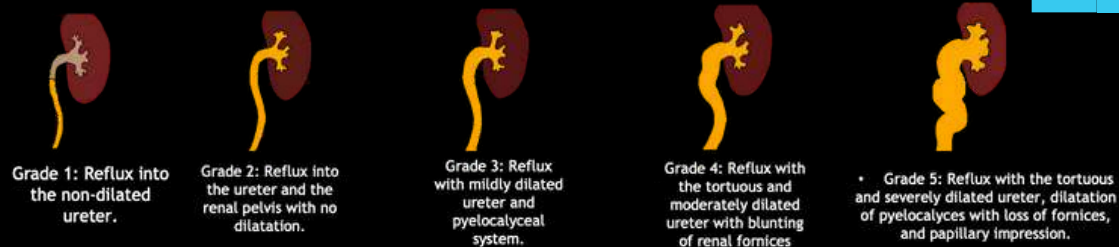


DIVERTICULUM

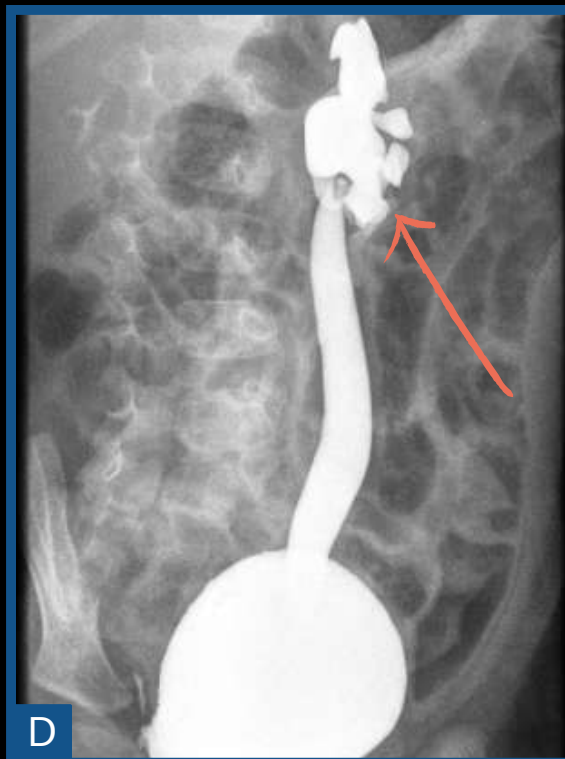

VESICoureTERIC REFLUX



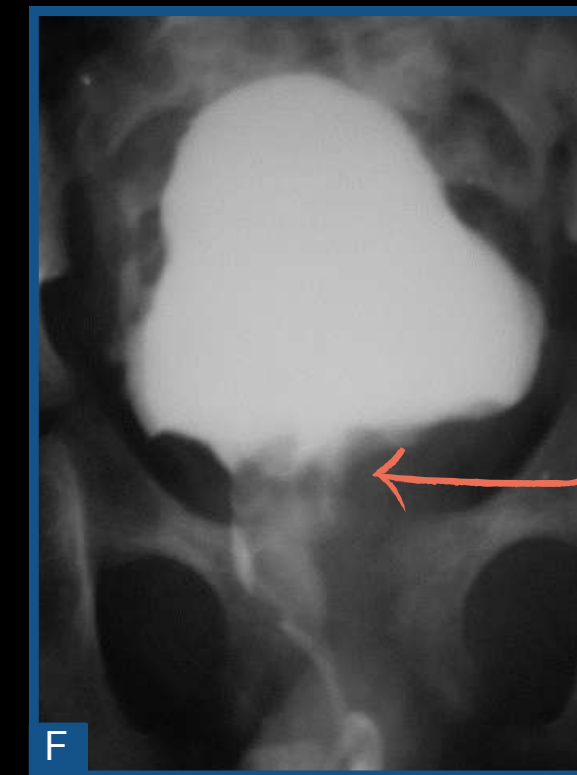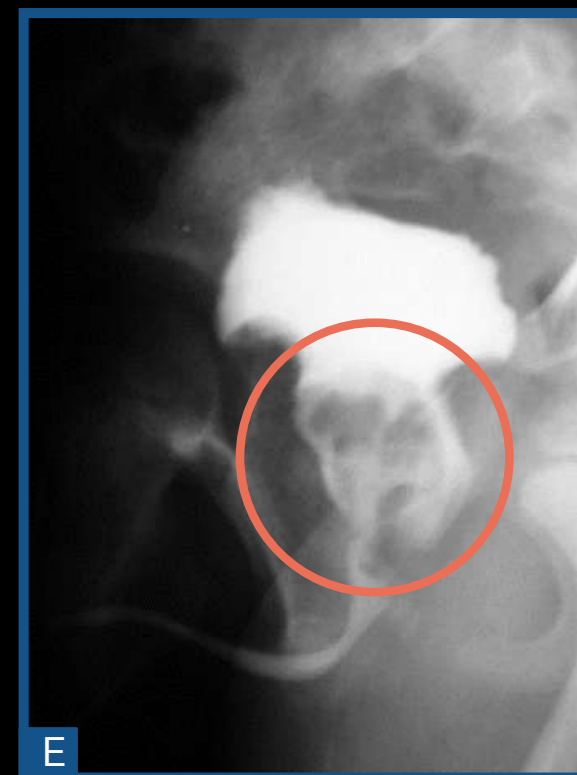Passive vesico-ureteral reflux to the right (blue arrow), grade I (C). Active and passive vesico-ureteral reflux to the left, grade IV (C, D).

BLADDER

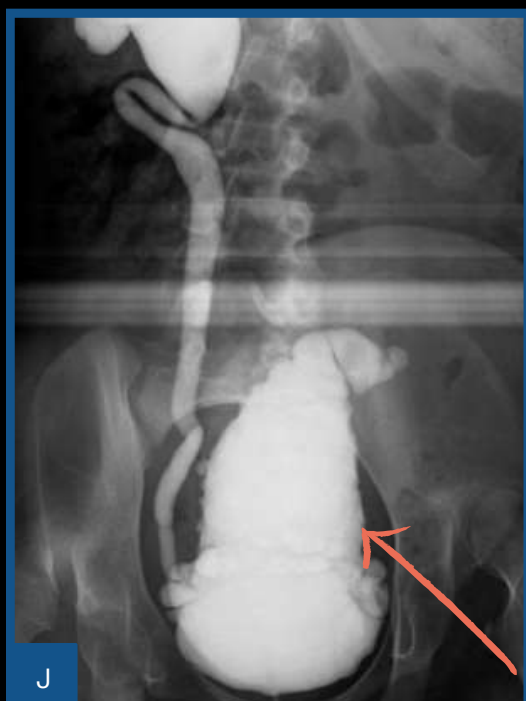
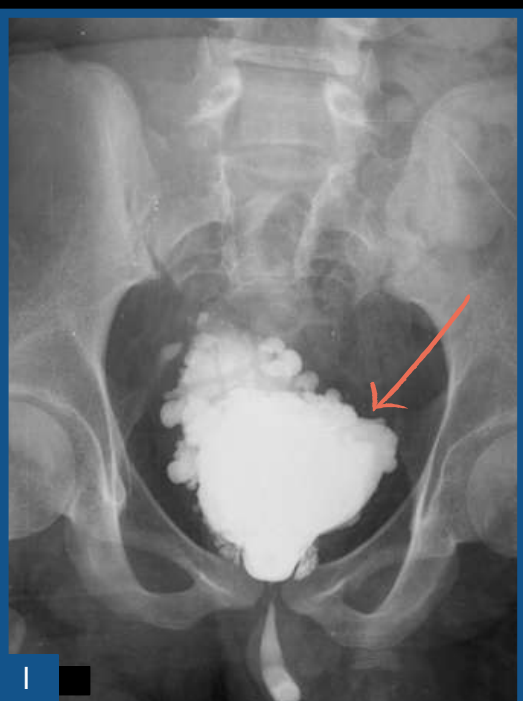

BOTRYOID SARCOMA

Presence of bladder filling failure (E, F), suggestive of a tumor.

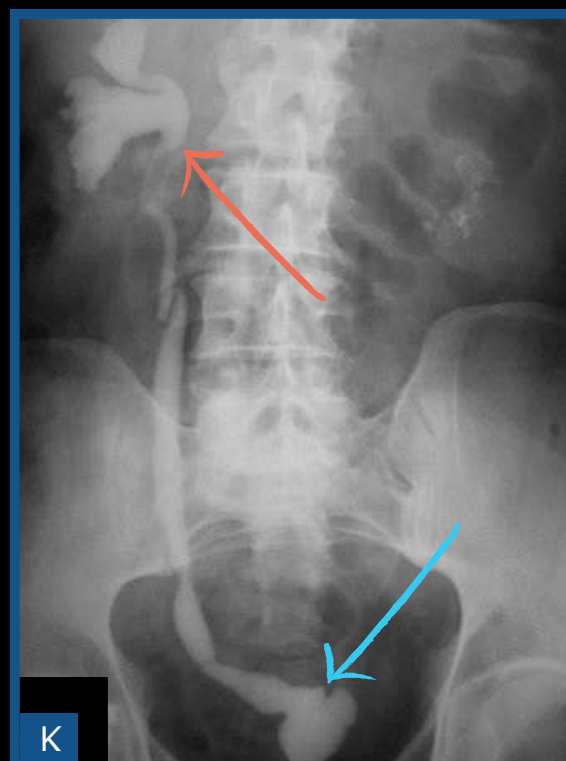


NEUROGENIC BLADDER



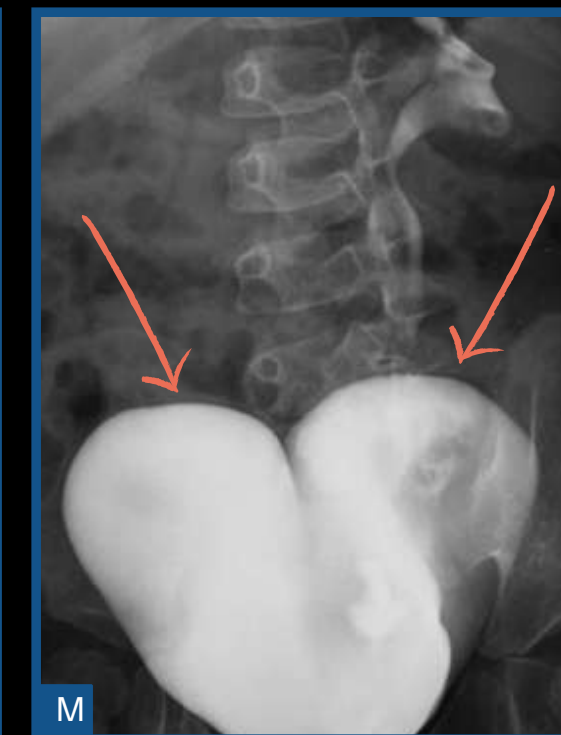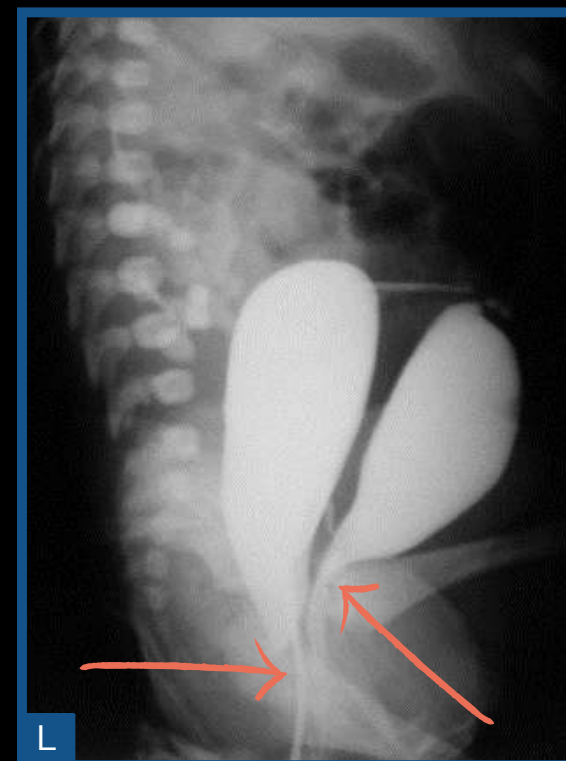Bladders are elongated with trabeculated walls and irregular contours (pine cone bladder), aspect that indicates overactive bladder. In addition, presence of multiple diverticula.

TUBERCULOSIS

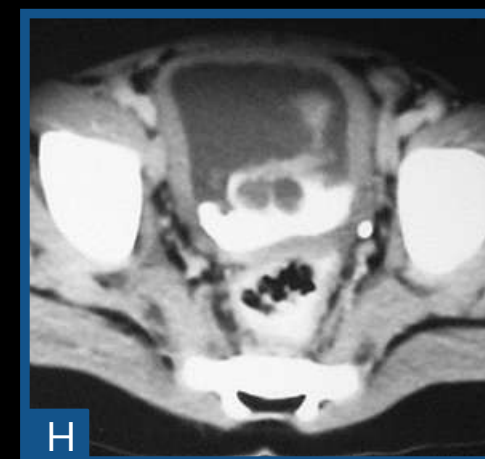
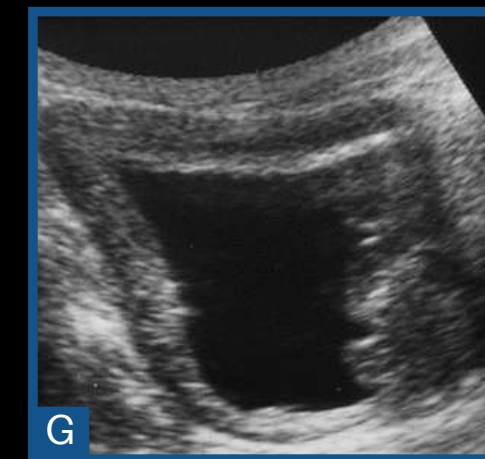


Contracted bladder (blue arrow) with associated vesicoureteral reflux (orange arrow)

DOUBLE BLADDER

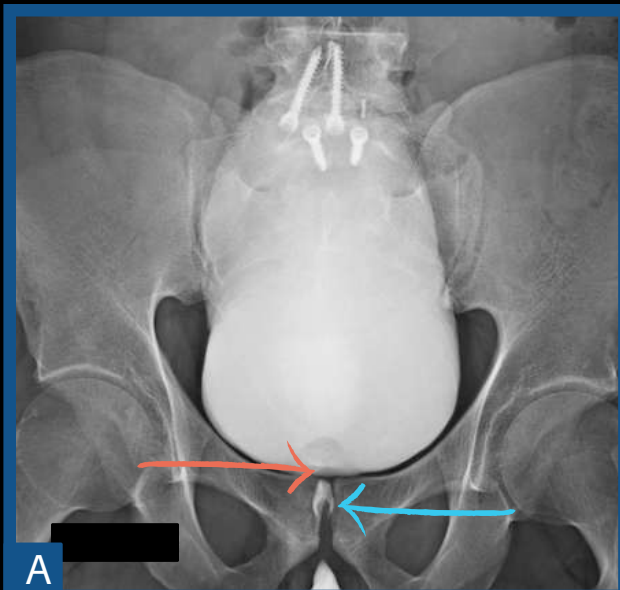


US (G) and axial CT (H), with a vegetative lesion in the bladder (arrows).

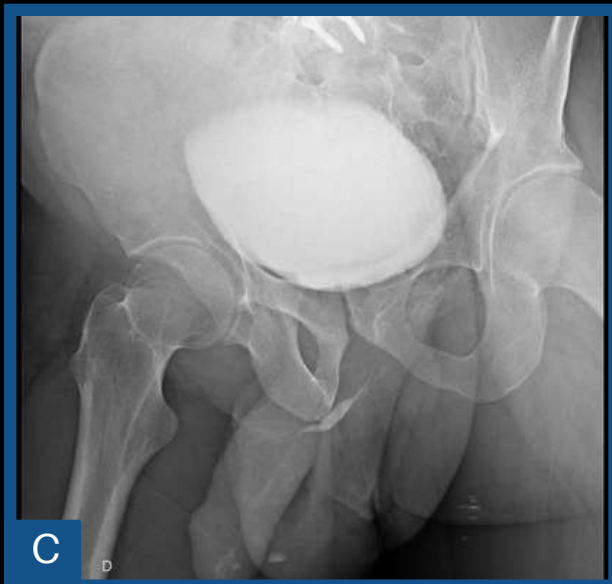
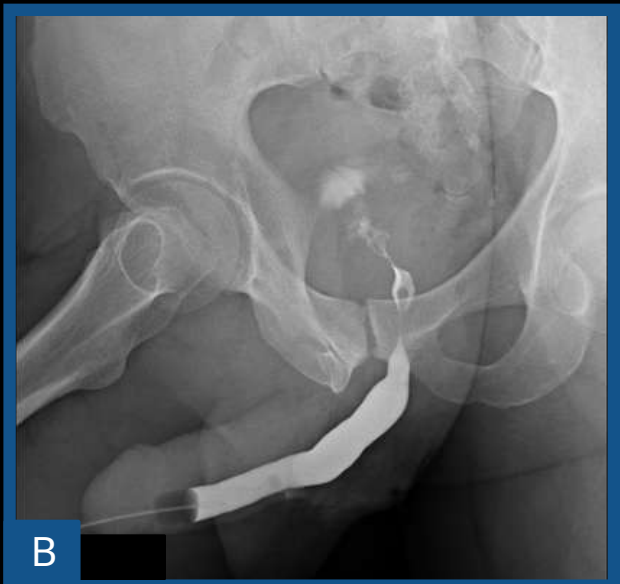




MARION'S DISEASE?



Significant narrowing at the level of the bladder neck (orange narrow), causing moderate difficulty in the retrograde passage of the contrast (B) and filiform path of the entire uretra to the voiding phase (C). Verumontanum (blue arrow)



ACCORDING TO THE LITERATURE:

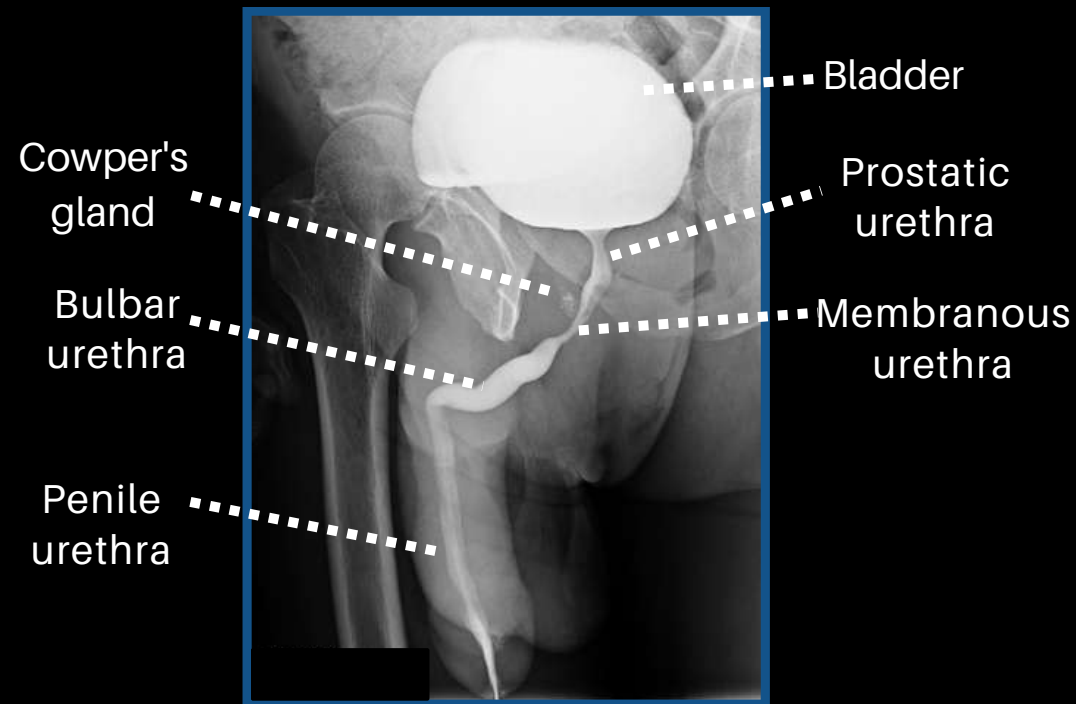
"Contract of the bladder neck, sometimes called idiopathic bladder neck obstruction (Marion's disease), may be either congenital or acquired. (...)

The verumontanum often was enlarged in these cases, and there was at times a diminution of the muscular-glandular tissue. (...)"

Radiographic atlas of the genitourinary system, Ney and Friedenberg.

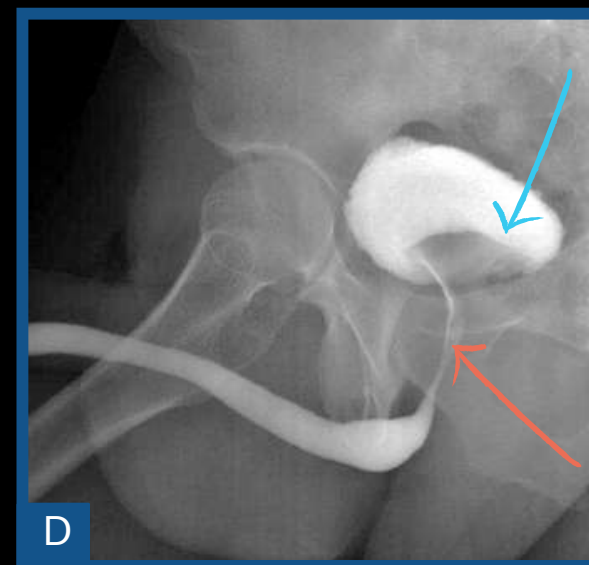
POSTERIOR URETHRA

NORMAL

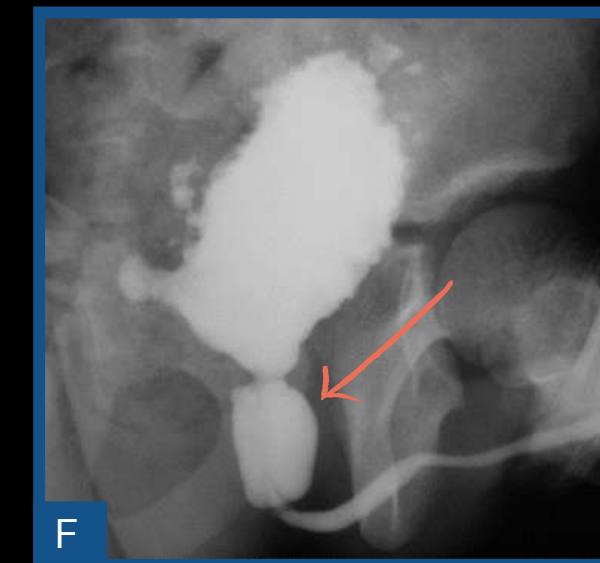
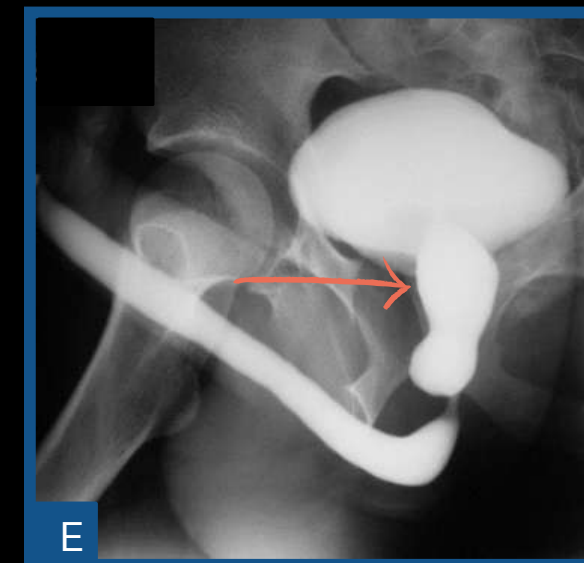


URETHRAL STRICTURE DUE TO PROSTAT GROWTH

Narrowing and stretching of the prostatic urethra (orange arrow) and bladder floor elevation (blue arrow).

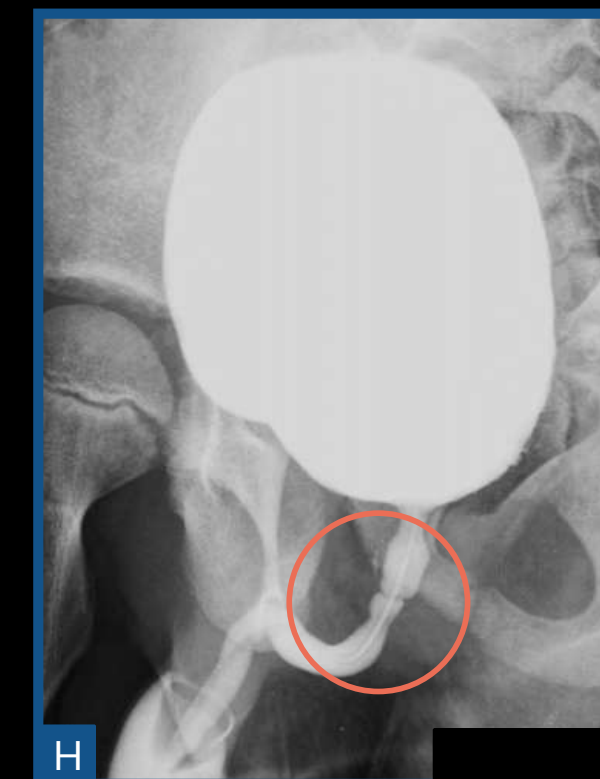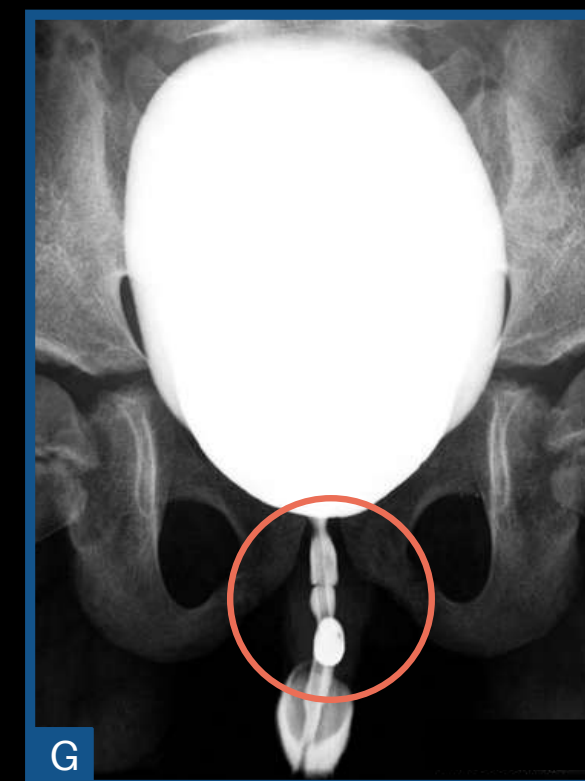


POSTERIOR URETHRA VALVE



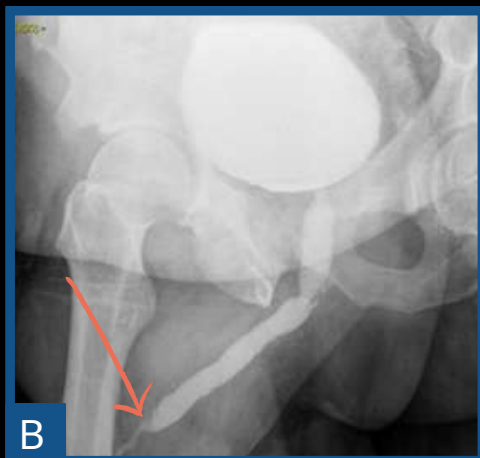
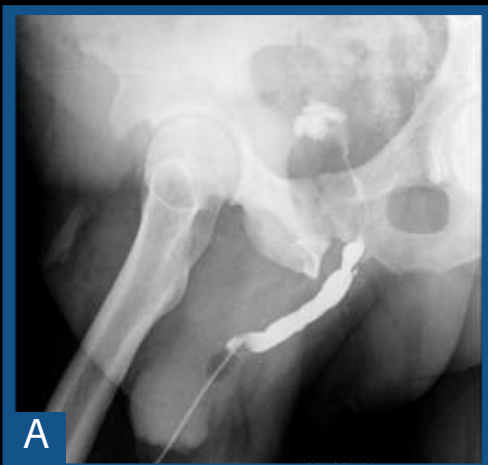
Presence of posterior urethral valve (arrows).

COBB NECKLACE (TYPE I)




Non-obstructive ring-shaped narrowing at the level of the posterior urethra (circles), suggesting Cobb ring (posterior urethral valve type 1).

URETHRAL STRICTURE



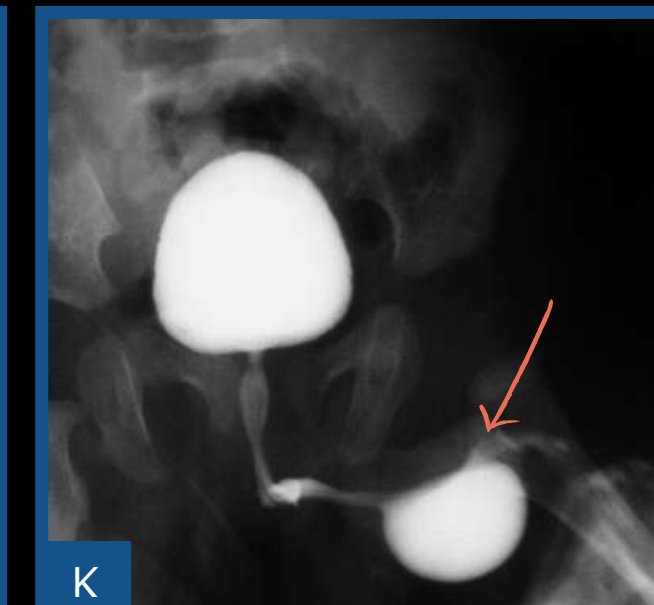
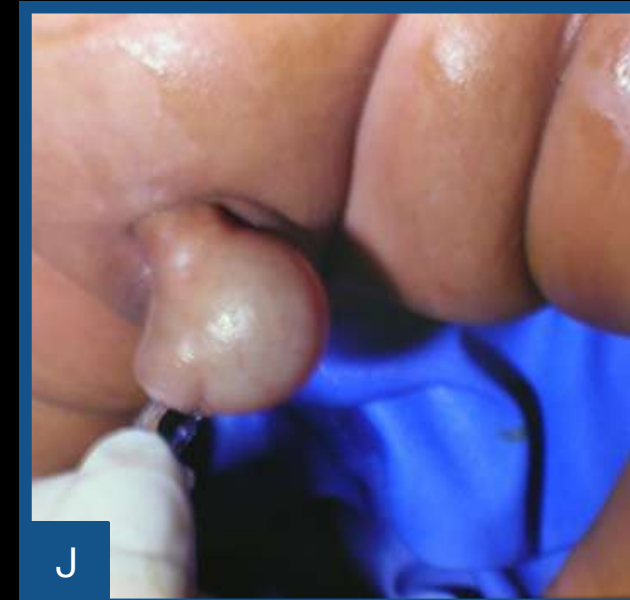Male voiding cystourethrogram (VCUG) and retrograde urethrogram (RUG) revealing distal urethral stricture (arrow)

Importance of performing a joint study (retrograde + voiding phase). 

ANTERIOR URETHRA

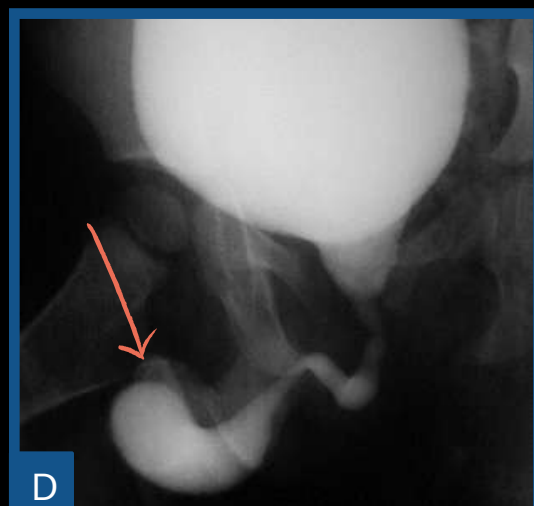
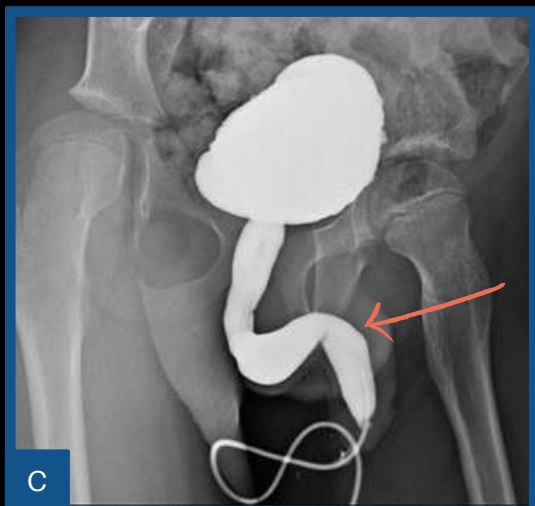
CONGENITAL

Male VCUG revealing distal urethral diverticulum (K) that was detected during examination before the exam (J)

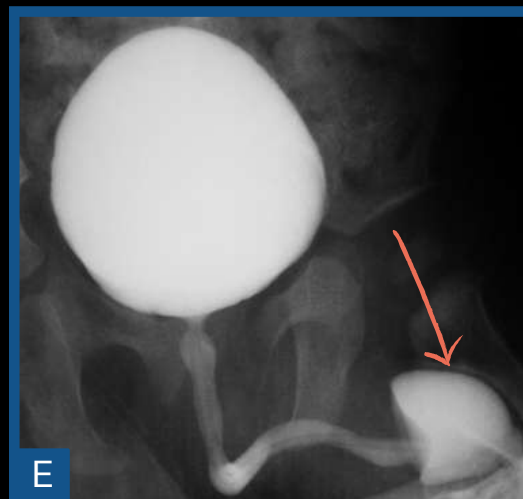


DIVERTICULUMS

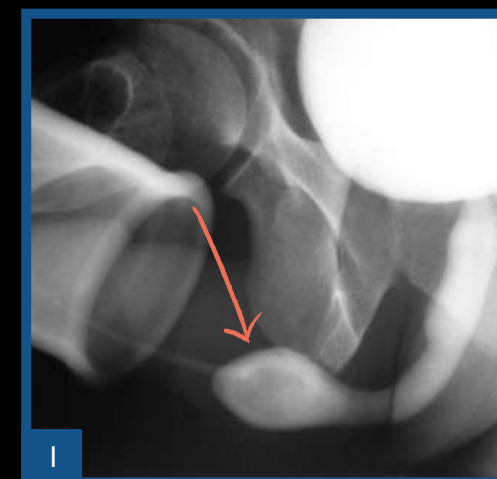
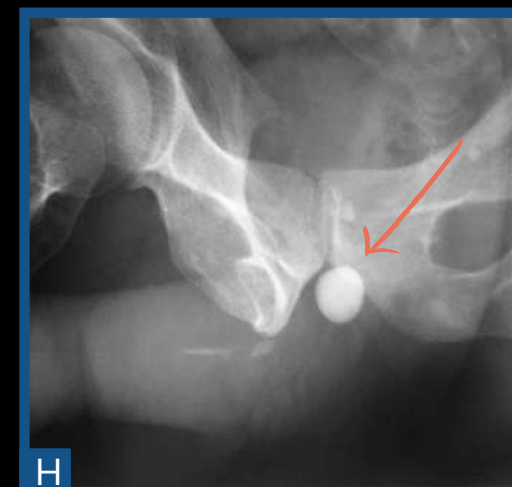
MEGALOURETHRA



PHIMOSIS

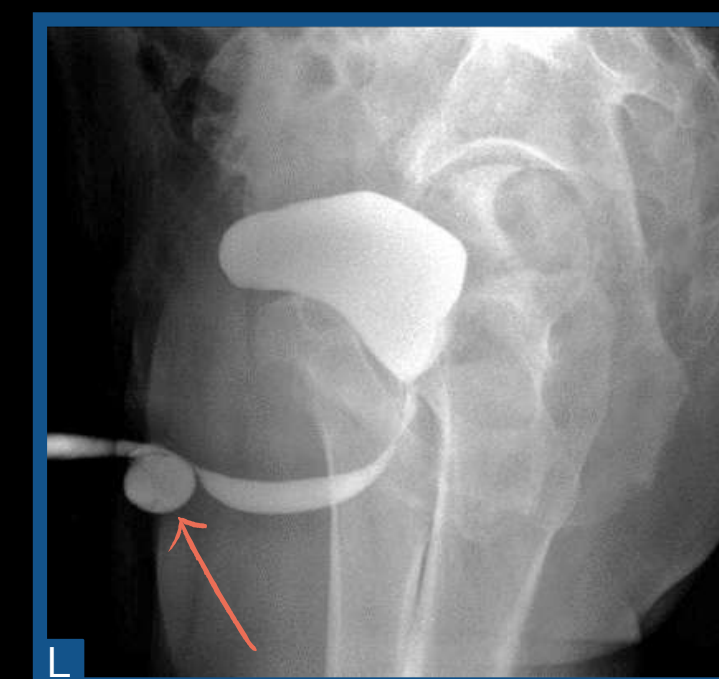


URETERAL CALCULUS

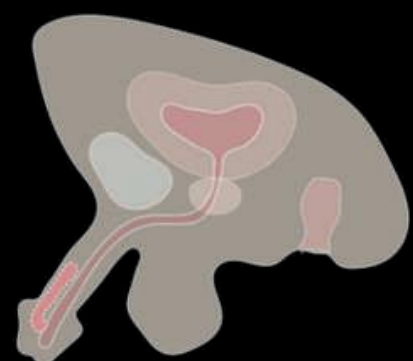


ACQUIRED

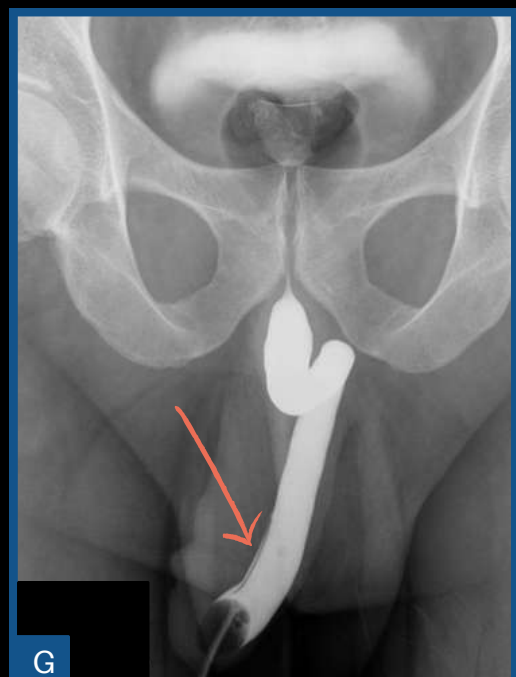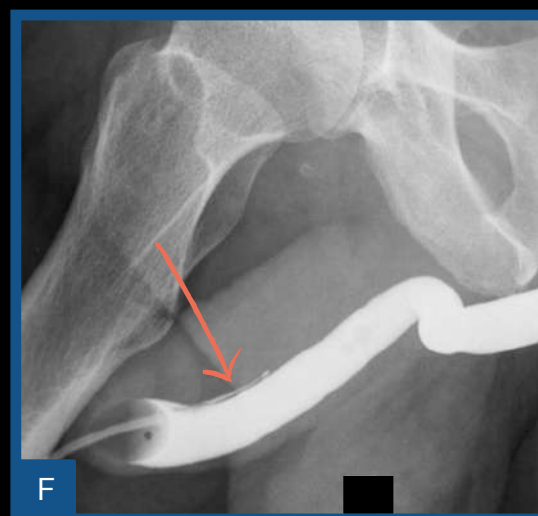
Presence of urethra diverticulum (L), in anterior segment, diagnosed after prostate surgery (arrow)



URETHRAL DUPLICITY

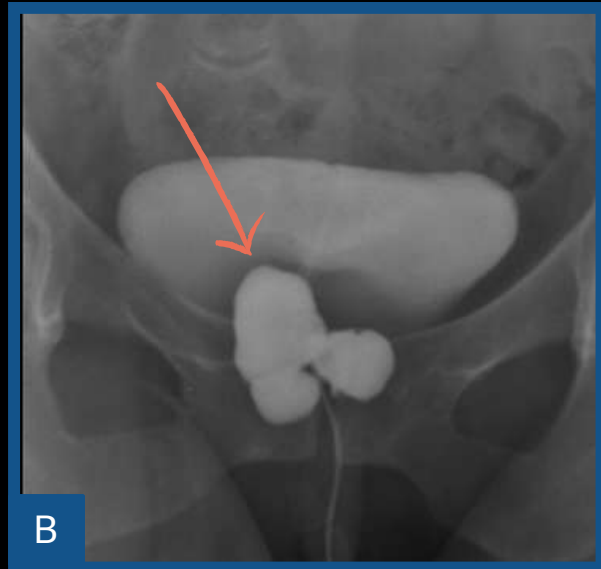
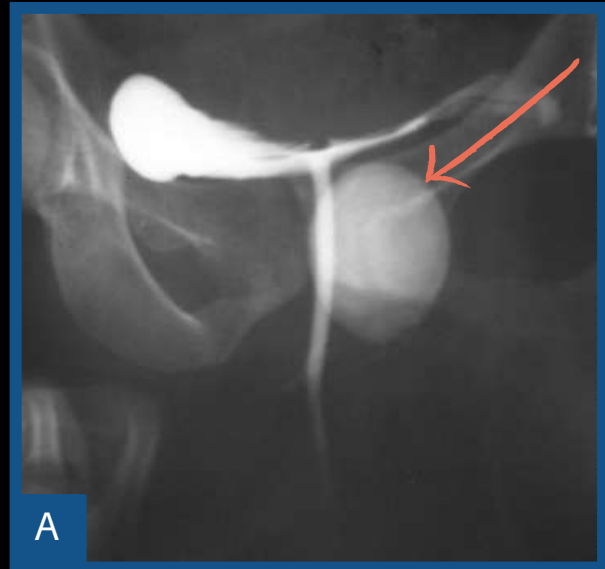


Male RUG, oblique (F) and anteroposterior (G) revealing urethral duplication (arrows), type 1.



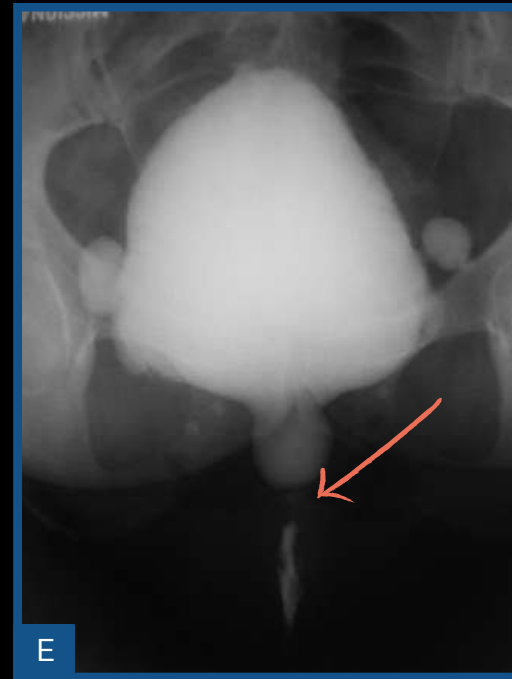FEMALE FINDINGS

DIVERTICULUMS



Paraurethral saccular formation.

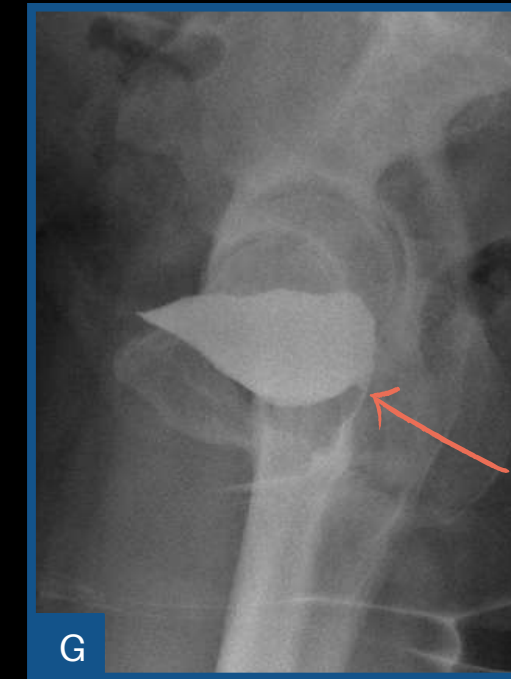
URETHRAL STRICTURE



Urethral meatus stenosis.

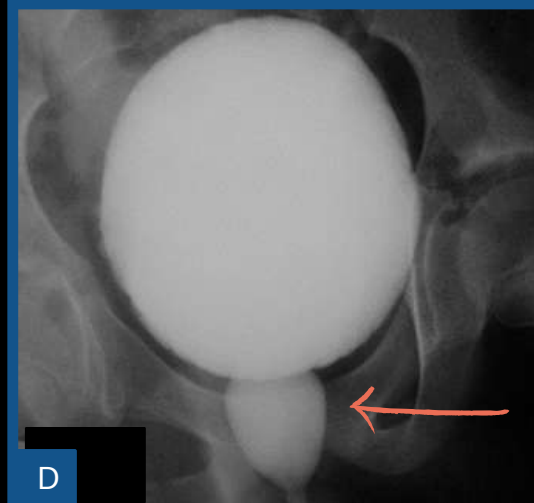
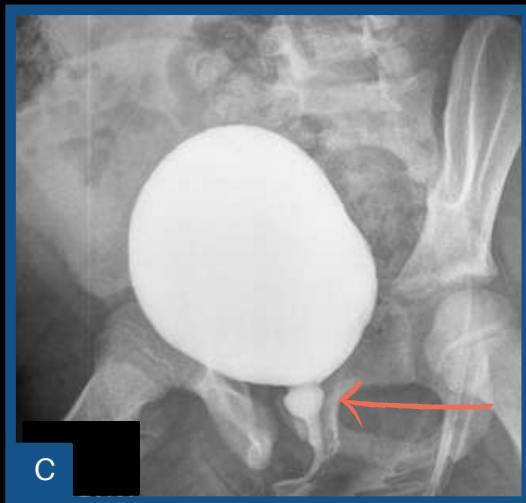
FISTULAS

VESICOVAGINAL



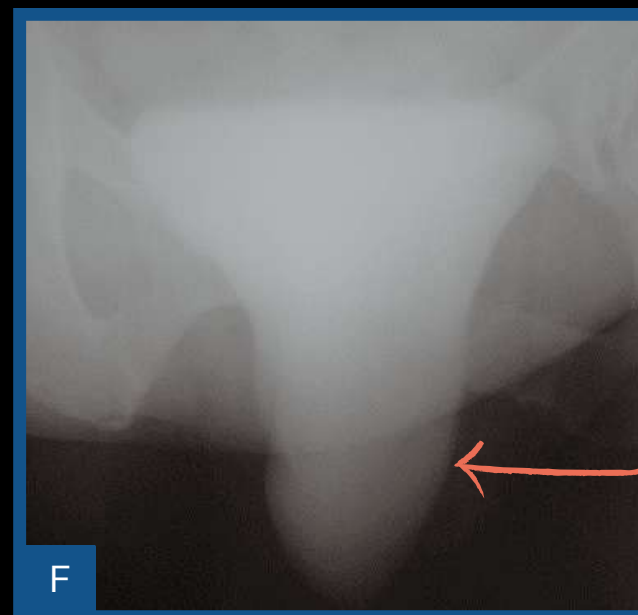
Presence of irregularity in the bladder wall, in a female patient, outlining a fistulous path towards the vagina with the presence of contrast at the first voiding (orange arrow).

SPINNING TOP URETHRA



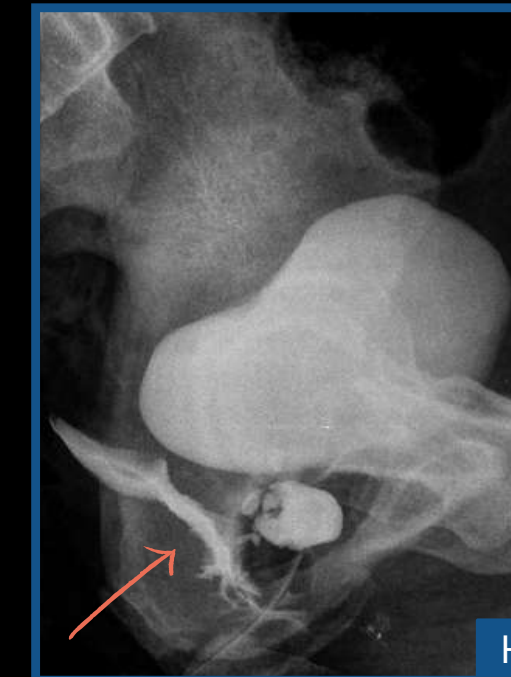
Dilated aspect of the urethra, with a "spinning top" aspect, during the voiding phase (lower urinary tract dysfunction).

CYSTOCELE



Bladder floor lowering.

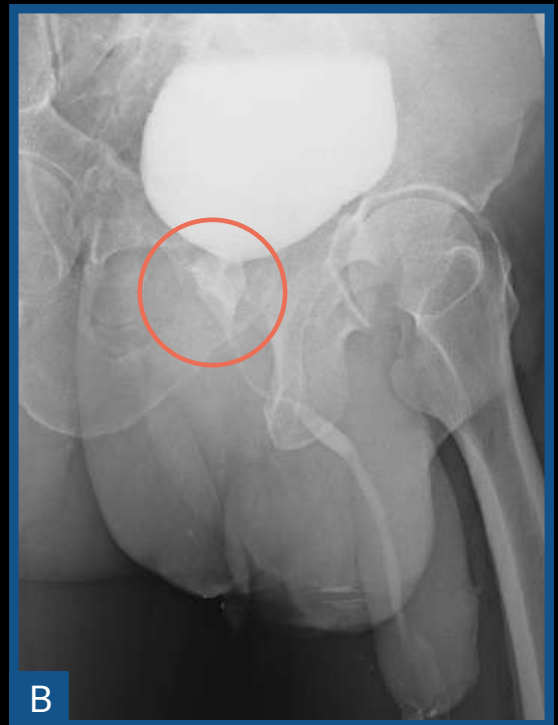
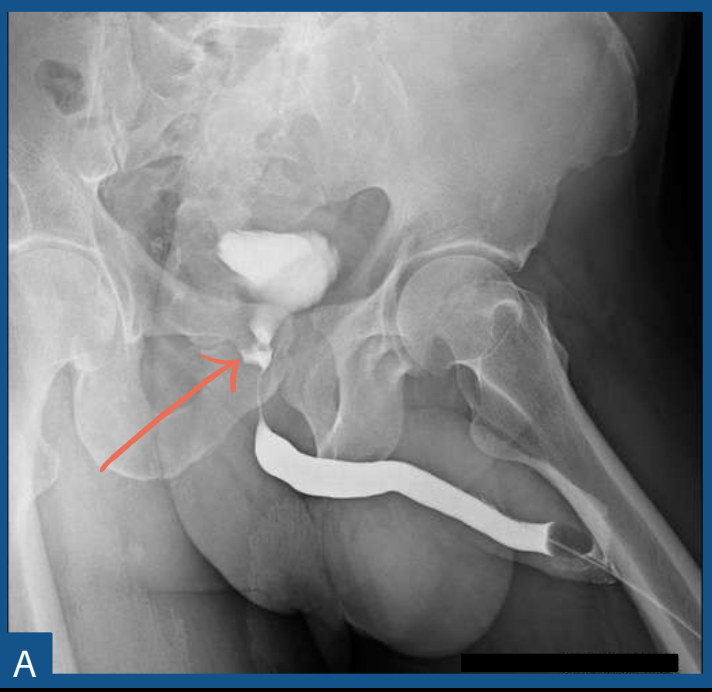
URETEROVAGINAL



Presence of irregularity in the posterior urethra, in a female patient, outlining a fistulous path towards the vagina (H) with the presence of contrast at the first voiding (orange arrow).

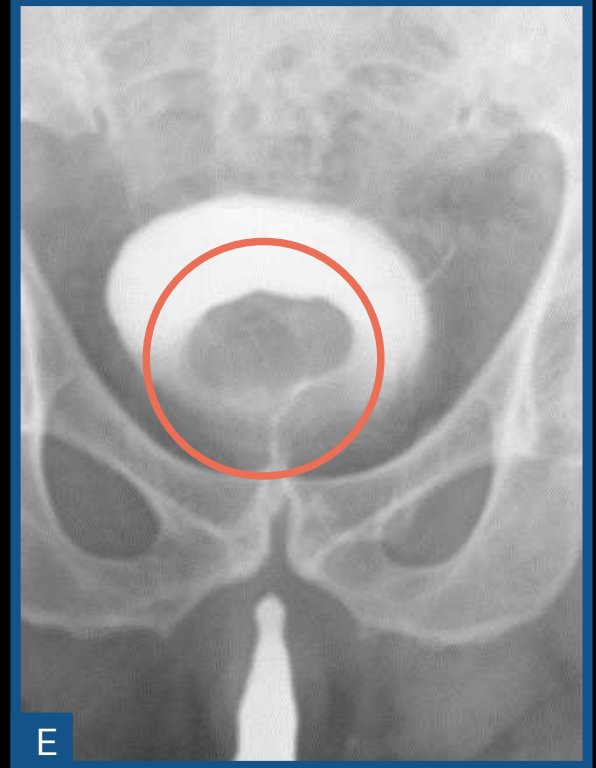PROSTATE

TRANSURETHRAL RESECTION OF THE PROSTATE (RTUP)

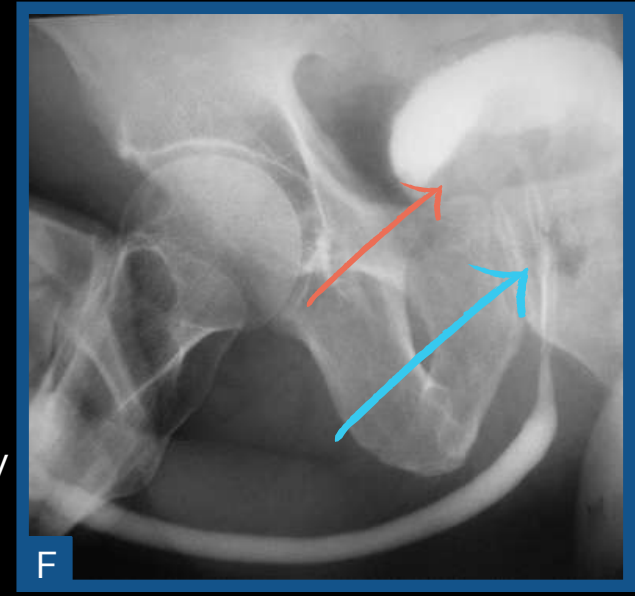
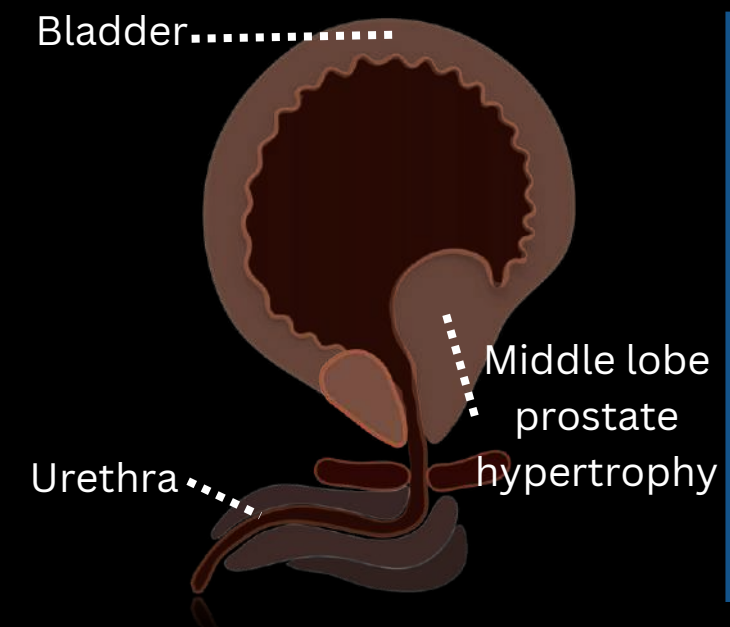


Previous surgical manipulation of the prostate (orange circle and arrow).

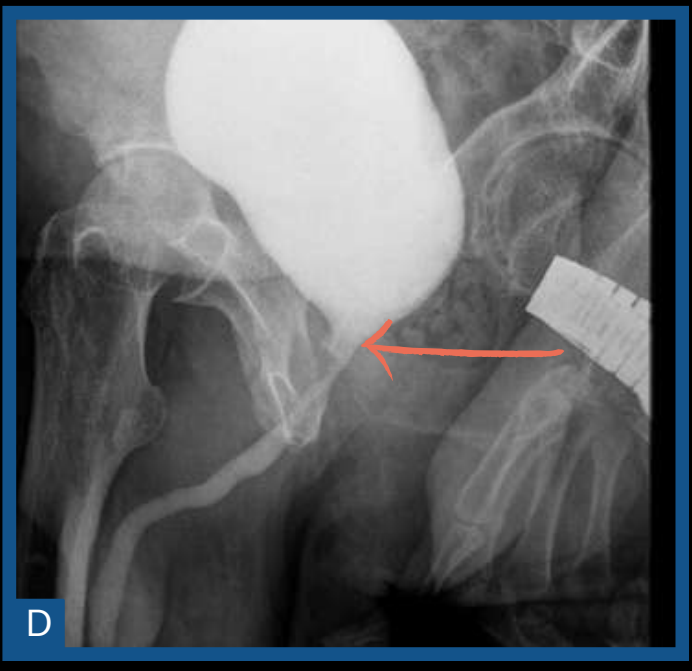
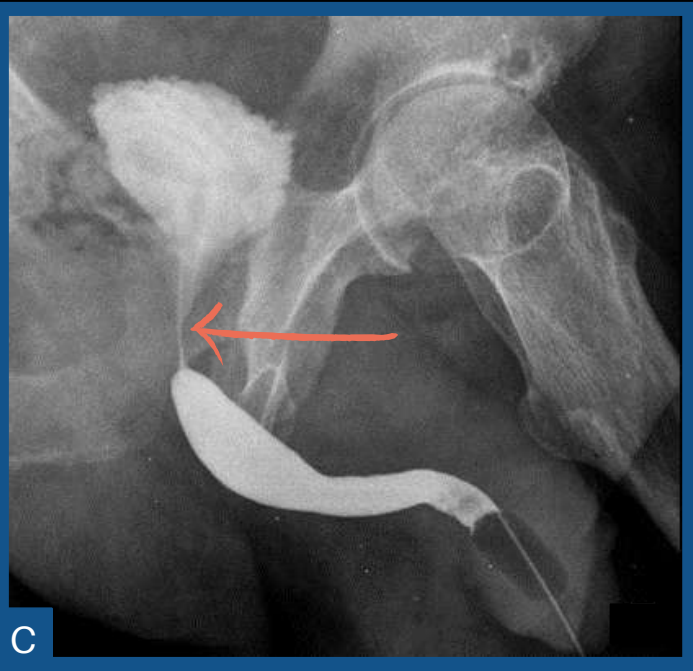
BENIGN PROSTATIC HYPLERPLASIA (BPH)



Presence of rounded filling failure in the bladder (E) due to median lobe prostate hypertrophy (circle). Stretching and narrowing of the prostatic urethra (blue arrow) associated with bladder lifting (F)

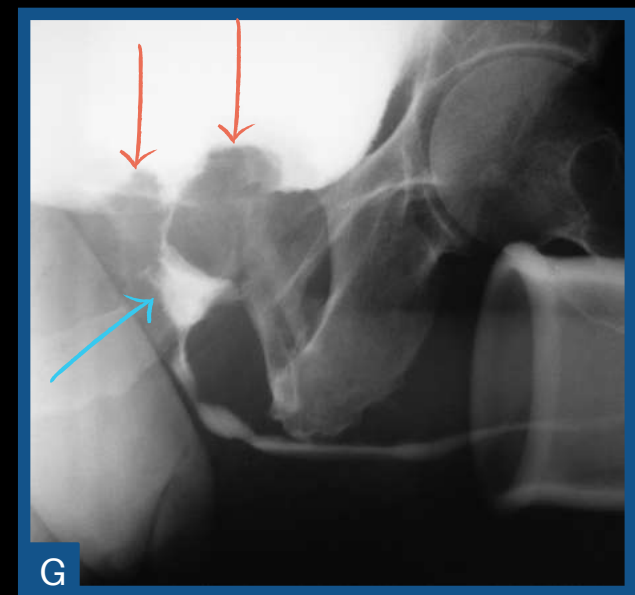


RADICAL PROSTATECTOMY



Shortened and narrowed aspect of the posterior urethra (arrows).

CANCER



Irregular elevation of the prostate floor (orange arrows) and presence of prostatic store from previous surgical manipulation (blue arrow).

REFLUX TO PROSTATIC DUCTS

Stretching and narrowing of the prostatic urethra (orange arrow) with bladder floor lifting (blue arrow) and posterior urethral calculus (circle)

