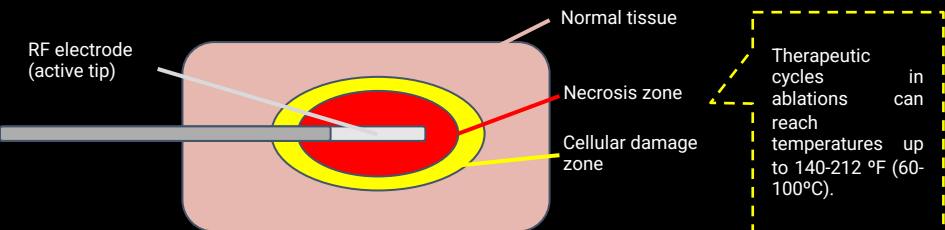
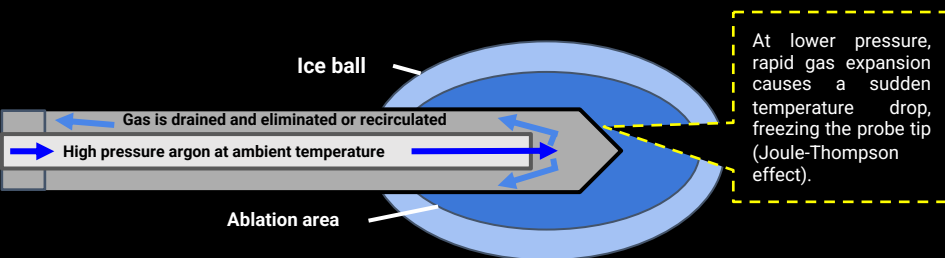


# PERCUTANEOUS ABLATIONS IN MUSCULOSKELETAL RADIOLOGY: AVOIDING THERMAL INJURIES

## RADIOFREQUENCY

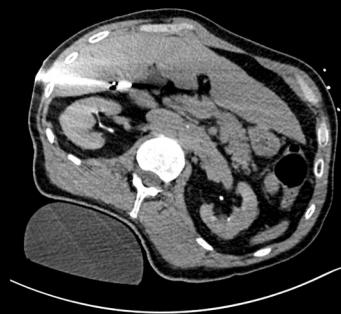

## CRYOABLATION

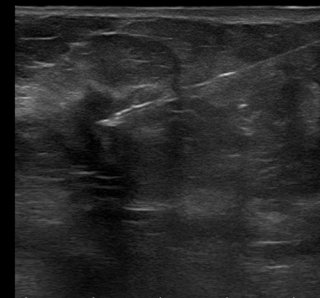


## OTHER TYPES OF PERCUTANEOUS ABLATION

### Microwave ablation (MWA)



### Interstitial laser



## COMPLICATIONS

Some of the potential complications associated with musculoskeletal percutaneous ablation techniques include:

Fractures

Infection

Bleeding

Neurovascular injury

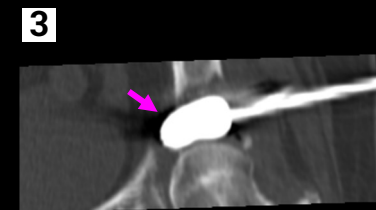
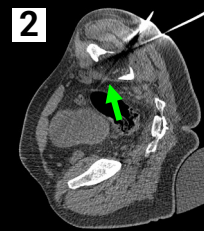
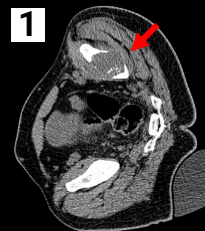Skin burn

Skin frostbite

Organ perforation

## THERMAL PROTECTION

Not only the ablation procedure needs protective measures to the surrounding tissues. It is important to remember that some stabilization techniques (cementoplasty) can use materials that promote exothermal reactions, rising temperature where it is applied. This demands additional caution when superimposed to the heat of ablation performed immediately before. Also, delaying cementoplasty after ablation is necessary to avoid too-rapid cement consolidation caused by higher temperatures.



53 year old male patient with a of a acetabular roof lytic lesion (red arrow) underwent cryoablation procedure (green arrow). After that, acetabuloplasty was performed with cement injection (purple arrow) aiming to preserve hip function.

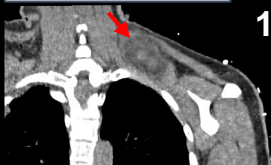## Monitoring

CT scan of a suprascapular desmoid tumor of a 46 yo patient.

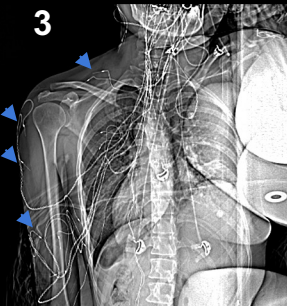
Also, temperature can be assessed with specific probes, knowing that spinal cord and peripheral nerves are safe between 50 and 113 °F. Over that, neurotoxic effects can be seen.

It is important to remember that as RFA uses electrical current, it can interfere with electroneuromyography if electrodes are near the ablation area. On these situations, if neural monitoring is necessary, cryoablation can avoid this problem because does not depend on electrical current.

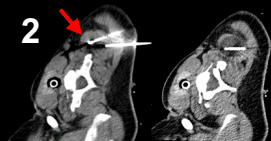1-2: suprascapular desmoid tumor treated with cryoablation (red arrows), adjacent to brachial plexus. 3: CT scan scout shows electroneuromyography monitoring devices (blue arrows) on the brachial plexus area. No damage to the neural branches was found near the ablation area.



1

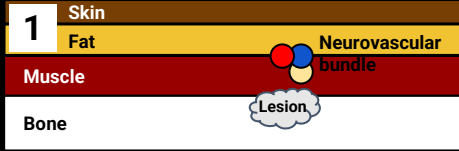


3

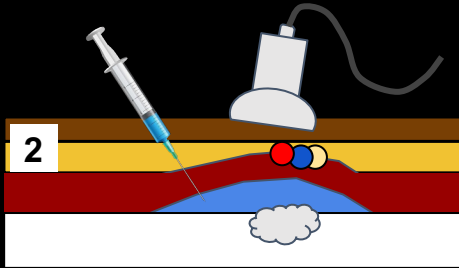


2

# Hydrodissection

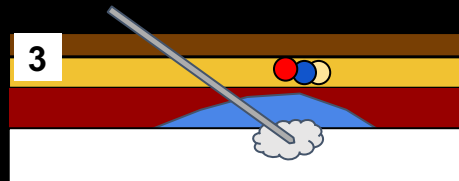


The objective is to create a protective buffer around the lesion, reducing the risk of thermal injury to nearby critical structures during the thermoablation procedure. The injected fluid also serves as a heat sink, absorbing and dissipating heat generated during the ablation process. Radiofrequency should use a dextrose solution instead of saline to avoid electrical conduction.

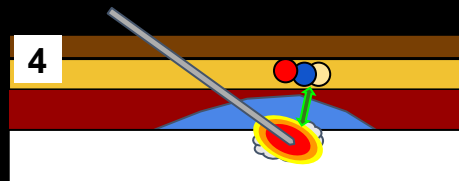


1: Illustration exemplifying simple anatomy of a target bone lesion.

2: Injection of a sterile fluid, typically a dextrose solution into the target area surrounding the lesion via a fine-gauge needle, guided by imaging modalities such as ultrasound or CT for precise placement in a variable volume as needed.

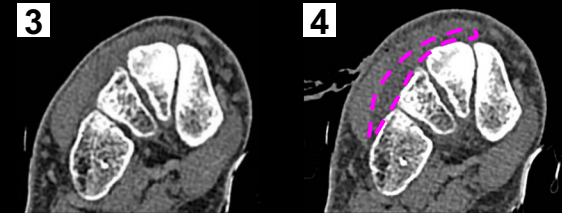
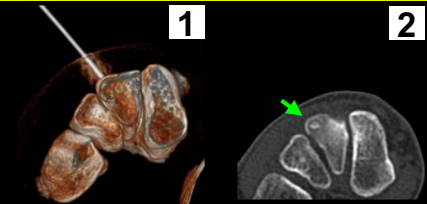


3: As it accumulates, it effectively separates and pushes aside adjacent tissues, including nerves, blood vessels, and other non-target structures. After that, the probe is placed in its definite position.



4: Then, when ablation produces heat locally, important structures as neurovascular bundles are kept in a safe distance from the high and potentially lesive temperatures.

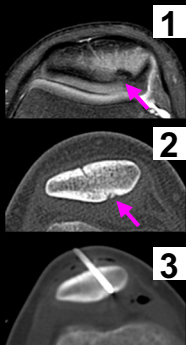
18 years old male, underwent percutaneous CT-guided radiofrequency ablation of an intermediate cuneiform osteoid osteoma in right foot. A 1.0cm Cooltip probe was used. After general anesthesia and local infiltration with ropivacaine, hydrodissection technique was performed using 5% dextrose solution and ropivacaine to separate adjacent soft tissue structures and within the joint space.



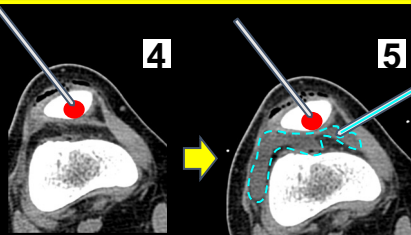
1: 3D CT reconstruction of probe positioning. 2: osteoid osteoma on dorsal aspect of intermediate cuneiform (green arrow). 3: before hydrodissection. 4: after 5% dextrose solution is injected deep in soft tissues, a hypodense area (purple dashed line) is observed where it is accumulated.

## Hydrodistension

Articular space hydrodistension (as an artificial joint effusion) generates a safe distance for the ablation area, by insulating effect and cooling/heating capability, depending of fluid temperature. The same principle applies to soft tissue hydrodistension, when a subcutaneous fluid injection creates a space and moves away adjacent structures.



T2 weighed FATSAT (1) and CT scans (2, 3) images of patella lesion with adjacent edema. 27 yo male with 2 years of local pain relieved by NSAIDs. Diagnosis of osteoid osteoma (purple arrow) was made, then radiofrequency ablation was used to treat it.

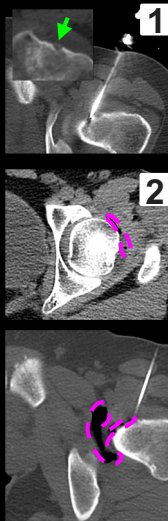


Continuous irrigation (blue dashed line) removes heat generated by radiofrequency.

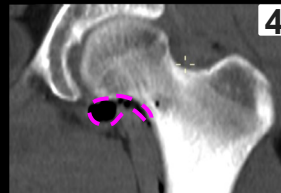As ablation occurs (4, 5), heat (red circle) dissipates through tissues, and articular space is distended by cold 5% glucose solution. Saline solution has electric conductivity, being not recommended in this context.

## Pneumodissection

Pneumodissection commences with the injection of a sterile gas, often carbon dioxide (CO<sub>2</sub>), into the anatomical region encompassing the targeted lesion or tissue. As the gas accumulates within the interstitial spaces, it serves as an effective separator, displacing and insulating adjacent tissues, including nerves, blood vessels, and healthy structures. However, it does not participate significantly in cooling or heating. Gases are capable of absorption by tissues, and may need additional injection during the procedure.

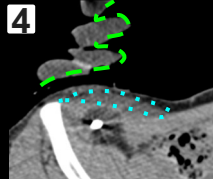
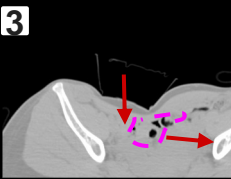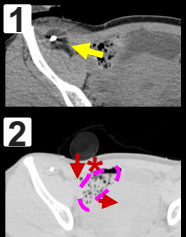


1: CT scans of a 19 yo male with a femur neck osteoid osteoma (green arrow), treated with radiofrequency ablation. 2-4: air (purple dashed line) was injected in the articular space and adjacent structures (pneumodissection) to insulate and distance tissues from ablation area.

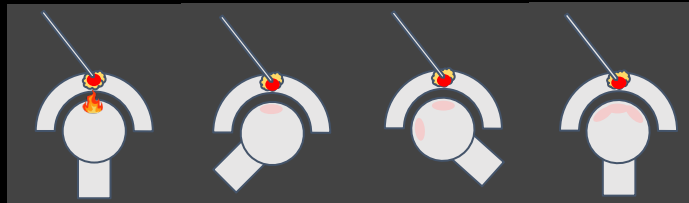


## Manual manipulation

Another way to use manipulation in thermal protection, especially in radiofrequency ablation (RFA) near joints, is passive joint movement with the aim of alternating the area in contact with high temperature to prevent heat concentration at a single point. An example of this is, in acetabular roof injuries, moving the thigh to different positions to avoid thermal injuries.



1-4: CT scans of a 34 yo female with a right iliac fossa desmoid tumor, undergoing radiofrequency ablation (yellow arrow). 2, 3: using bandages and cushions (red asterisk), pressure is made over the colon (purple dashed line), so it moves away from the cold area. 4: Hydrodissection (blue dotted line) was also used to distance skin from the ablation area. Over that, a glove with warm water (green dashed line) protect from frostbite.

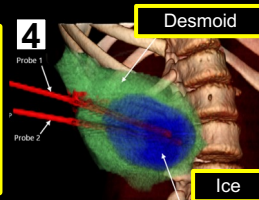
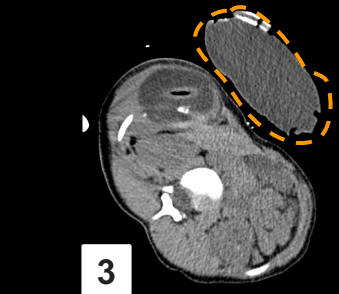
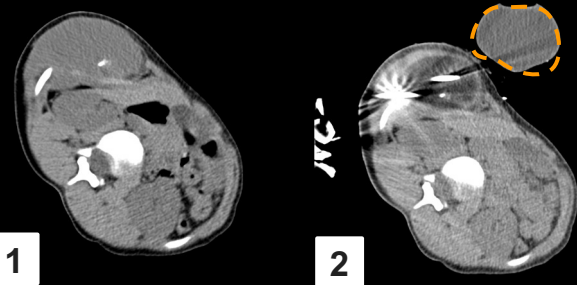


On the right, illustration of a hypothetical joint undergoing a RFA for a lesion in its roof. If heat is applied without position changes, chondral surface is in risk for lesion.

At the left illustration, movements allow heat distribution in a larger surface area, minimizing risk of burns and other thermal lesions.

## Skin warming/cooling

Both skin warming and cooling aim to maintain a controlled thermal gradient between the skin and deeper tissues. Skin warming ensures that the skin remains at a higher temperature than the target area in cryoablation procedures, minimizing the risk of superficial burns and various methods can be used, including warm saline packs or forced air warming systems. Skin cooling with cold compresses, cooled air, or even specialized cooling devices helps maintain a lower skin temperature in radiofrequency ablations, preventing overheating and thermal damage to the skin (frostbites).



1-4: CT scan shows a cryoablation of a desmoid tumor of thoracic wall on a 14 yo female. In this case, a warm water bag (orange dashed line) was positioned over the ablation area, to avoid possible freezing by adjacent ablation area. This can also be achieved by a sterile glove (green asterisk) filled with water. 4: 3D reconstruction of the lesion and ablation zone.

## TAKE HOME

Method	What can be used?	Notes
Monitoring	ENMG, SSEP, MEP, temperature monitoring, image evaluation	Depending on the proximity to electrodes and monitoring devices, RF can cause interference on some equipments.
Hydrodissection, hydrodistension	Dextrose 5% solution, saline solution	On RF ablations, avoid using saline solution by its electrical conductivity. Dextrose solution is indicated in these situations.
Pneumodissection	Carbon dioxide, air	Carbon dioxide has faster tissular absorption and lower risk for embolization.
Manual manipulation	Manual maneuvers, manual compression cushions, bandages	It includes articular manipulation to distribute heat on a larger area.
Skin warming/cooling	Bags with fluids in adequate temperature, air warming	